nature reviews disease primers

https://doi.org/10.1038/s41572-024-00492-3

Primer

Check for updates

Rotator cuff tears

Asheesh Bedi[1,2], Julie Bishop[3], Jay Keener[4], Drew A. Lansdown[5], Ofer Levy[6], Peter MacDonald[7], Nicola Maffulli[8], Joo Han Oh[9], Vani J. Sabesan[10], Joaquin Sanchez-Sotelo[11], Riley J. Williams III[12] & Brian T. Feeley[5]

Abstract

Rotator cuff tears are the most common upper extremity condition seen by primary care and orthopaedic surgeons, with a spectrum ranging from tendinopathy to full-thickness tears with arthritic change. Some tears are traumatic, but most rotator cuff problems are degenerative. Not all tears are symptomatic and not all progress, and many patients in whom tears become more extensive do not experience symptom worsening. Hence, a standard algorithm for managing patients is challenging. The pathophysiology of rotator cuff tears is complex and encompasses an interplay between the tendon, bone and muscle. Rotator cuff tears begin as degenerative changes within the tendon, with matrix disorganization and inflammatory changes. Subsequently, tears progress to partial-thickness and then full-thickness tears. Muscle quality, as evidenced by the overall size of the muscle and intramuscular fatty infiltration, also influences symptoms, tear progression and the outcomes of surgery. Treatment depends primarily on symptoms, with non-operative management sufficient for most patients with rotator cuff problems. Modern arthroscopic repair techniques have improved recovery, but outcomes are still limited by a lack of understanding of how to improve tendon to bone healing in many patients.

Sections

Introduction

Epidemiology

Mechanisms/pathophysiology

Diagnosis, screening and prevention

Management

Quality of life

Outlook

[1]Department of Orthopedic Surgery, University of Chicago, Chicago, IL, USA. [2]NorthShore Health System, Chicago, IL, USA. [3]Department of Orthopedic Surgery, The Ohio State Wexner Medical Center, Columbus, OH, USA. [4]Department of Orthopedic Surgery, Washington University, St. Louis, MO, USA. [5]Department of Orthopedic Surgery, University of California San Francisco, San Francisco, CA, USA. [6]Reading Shoulder Unit, Berkshire Independent Hospital, Reading, UK. [7]Department of Surgery, Max Rady College of Medicine, Winnipeg, Manitoba, Canada. [8]Department of Trauma and Orthopaedic Surgery, Faculty of Medicine and Psychology, University of Rome Sapienza, Rome, Italy. [9]Department of Orthopedic Surgery, Seoul National University College of Medicine, Seoul National University Bundang Hospital, Seoul, Korea. [10]HCA Florida JFK Orthopaedic Surgery Residency Program, Atlantis Orthopedics, Atlantis, FL, USA. [11]Department of Orthopedic Surgery, Mayo Clinic, Rochester, MN, USA. [12]Department of Orthopedic Surgery, Hospital for Special Surgery, New York, NY, USA.
e-mail: Brian.feeley@ucsf.edu

Introduction

The rotator cuff is a group of muscles and tendons that maintains the shoulder in place and provides dynamic motion and stability to the joint. It is composed of four separate muscles, namely the supraspinatus, infraspinatus, subscapularis and teres minor. The tendons from these four muscles coalesce at their attachments on the humeral head (Fig. 1). The glenohumeral joint has the greatest range of motion of any joint in the human body, and inherently relies upon the rotator cuff to provide dynamic stabilization as well as function to position the arm and hand.

Rotator cuff tears are the most common upper extremity condition seen by primary care physicians, physiatrists and orthopaedic surgeons[1]. Rotator cuff injuries present as a spectrum of disease ranging from tendinopathy and partial-thickness tears, extending to full-thickness tears with progressive cartilage degeneration (cuff tear arthropathy)[2] (Box 1 and Fig. 2). Symptoms of rotator cuff injuries are broad and can range from minimal symptoms including difficulty sleeping and pain during overhead reaching to loss of active and passive motion with progressive shoulder girdle weakness and dysfunction.

Although some tears are traumatic, most rotator cuff problems are degenerative in nature due, in part, to age-related changes to the tendon structure. The leading hypothesis is that tears progress from tendinopathic changes in a watershed area that lacks blood supply in the supraspinatus to partial-thickness tears and eventually full-thickness tears[3], which are accompanied by progressive muscle and tendon degeneration. Confounding the natural history is that not all tears progress and/or worsen, and in many patients who present with a progressive increase in the tear size, symptoms do not worsen, making a standard algorithm for treatment challenging[4,5].

The pathophysiology of rotator cuff tears is complex, as it involves the interplay between the tendon, bone and muscle. A key to understanding rotator cuff pathology and tearing is delineating the role of tendon and muscle degeneration. Increasing evidence suggests that the mTOR pathway might have an important role in the regulation of tendon degeneration over time[6]. Muscle quality, as evidenced by the overall size of the muscle, as well as intramuscular fat deposition (fatty infiltration) also influences shoulder strength, tear progression and the outcome of surgery[7]. Studies also highlight the role of fibroadipoprogenitor cells (FAPs) (muscle-resident multipotent mesenchymal stem cells (MSCs)) as a central mediator of muscle degeneration[8,9].

The management of rotator cuff tears is generally based on symptoms. Indeed, most patients with rotator cuff tears diagnosed on advanced imaging (for example, MRI or ultrasonography) do not require surgery. Observation, physical therapy and corticosteroid injections, as well as surgical repair and reconstruction of the rotator cuff, all play a role in patient recovery, which depends on many patient-specific factors such as age, activity level and hand dominance, and intrinsic factors of the rotator cuff.

Of note, the terminology of rotator cuff disease in the literature varies: a rotator cuff problem is described as a tendinopathy, a tear, an injury or rotator cuff disease. Thus, the nomenclature leads to confusion for the patient and the provider.

In this Primer, we present the current knowledge of the basic and clinical science of rotator cuff disease, highlighting the clinical presentation, natural history, risk factors and current treatment options. Furthermore, we provide an evidence-based treatment algorithm and consolidate the unmet needs in the field as well as outline the barriers necessary to overcome the modest improvements in outcomes of surgery over the past 20 years.

Epidemiology

Prevalence

Patients can develop shoulder pain at any point along the spectrum of rotator cuff tears. Most patients with a rotator cuff tear do not have symptoms of pain or weakness and do not seek medical care. Hence, the exact prevalence of rotator cuff disease is unknown. Although the incidence of symptomatic rotator cuff disease is probably steady, rotator cuff repair surgery is more common than 20 years ago, probably due to the increased use of arthroscopic techniques and transition to outpatient surgery. One study showed an annual increase in rotator cuff surgery of 1.6% per year in the USA between 2007 and 2016 (165 repairs per 100,000 person-years[10]). In the absence of pain, individuals with rotator cuff tears have been shown to maintain nearly normal shoulder function[11]. Population screening studies using shoulder ultrasonography have better defined the prevalence of rotator cuff tear[12]. A cross-sectional study involving 1,000 women in the UK demonstrated that 22.2% had a full-thickness rotator cuff tear. Advancing age and dominant shoulder involvement were positively correlated with the presence of a tear. Similarly, two different observational studies in Asian populations showed a prevalence of full-thickness cuff tears of 20.7% (1,366 individuals) and 22.1% (664 individuals), with higher prevalence in individuals ≥57 years of age than in younger individuals and in men than in women[13,14].

Risk factors

Age. The overwhelming clinical evidence suggests that the primary risk factor for the development of rotator cuff degeneration is age[4,5,15,16]. Multiple clinical studies have shown that patients with a painful rotator cuff tear often have an asymptomatic degenerative tear in the opposite shoulder[5,11,17,18]. One study performed bilateral shoulder ultrasonography on patients presenting with unilateral shoulder pain, and demonstrated a strong association between cuff disease and ageing[19]. The presence of a full-thickness tear in the painful shoulder was associated with a 21% risk of a partial-thickness tear and 36% risk of a full-thickness tear in the contralateral shoulder. The average age of those with an intact cuff, a unilateral cuff tear and bilateral partial-thickness or full-thickness cuff tears demonstrated a nearly perfect 10-year distribution (48.7, 58.7 and 67.8 years of age, respectively)[17]. Patients with a full-thickness cuff tear on the symptomatic side had a 50% chance of having a concomitant cuff tear on the asymptomatic side at ≥66 years of age. One study involving pooled data from 30 separate studies and >6,000 shoulders demonstrated a strong correlation between the presence of a tear and increasing age stratified by decade, with a prevalence of 9.7% in those <20 years of age compared with a prevalence of 62% in those >80 years of age[20].

Genetics. Genetics may play a role in the development of rotator cuff disease (Box 2). One study demonstrated a familial association of rotator cuff disease, noting that siblings were twice as likely as spouses to develop a full-thickness cuff tear, regardless of symptoms, and more than four times as likely to develop a painful full-thickness tear compared with the general population[21,22]. Additionally, progression of tear size at 5-year follow-up was greater in siblings than controls[23]. Studies have shown an association between variants in genes related to cellular apoptosis on chromosome 6 and chromosome 17 and rotator cuff disease[24]. Indeed, genome-wide association studies have shown variants in multiple candidate genes using large population-based genetic databases[25,26]. RNA sequencing of the UK Biobank showed an increased expression of *STK24* and a decreased expression of *SAT1*

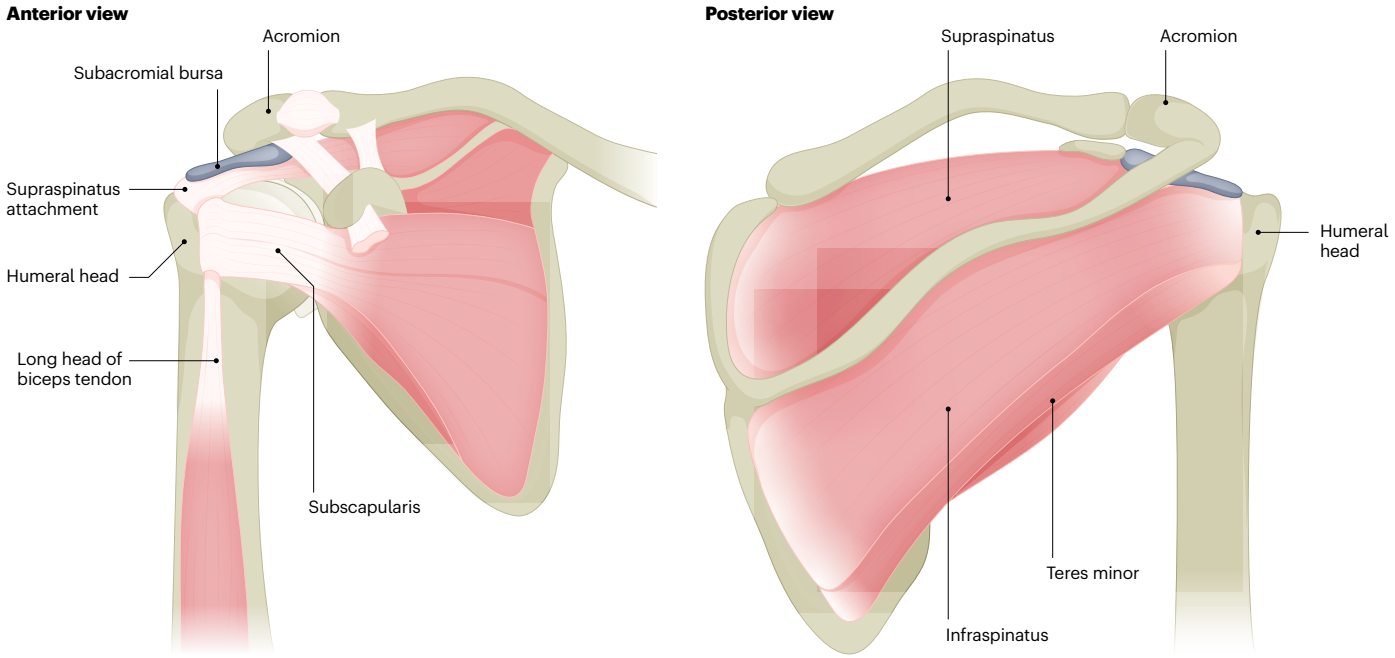

Fig. 1 | Structural anatomy of the rotator cuff when viewed from the anterior and posterior aspects. The tendons of the teres minor, infraspinatus and supraspinatus are continuous on the humeral head. The supraspinatus muscle lies on the superior portion of the scapula and inserts on the anterior aspect of the greater tuberosity of the humeral head. The primary function of the supraspinatus is forward and lateral elevation of the shoulder, and it assists in rotation of the arm. It is the most commonly torn rotator cuff tendon, involved in 70–85% of rotator cuff tears[13]. The infraspinatus lies below the scapular spine and attaches posterior to the supraspinatus on the rotator cuff. It functions to stabilize the shoulder against posterior subluxation and is the primary muscle responsible for external rotation of the shoulder. The teres minor lies below the infraspinatus, with a common origin along the medial border of the scapula. It provides up to 45% of the external rotation force. The subscapularis lies on the anterior portion of the scapula and attaches to the lesser tuberosity. Its primary function is internal rotation of the shoulder and it also acts as a force couple (along with the infraspinatus) against the deltoid, keeping the shoulder stabilized within the joint against the pull of the deltoid[302]. The long head of the biceps tendon runs between the supraspinatus and subscapularis in the rotator interval.

and *UBE2D3* following rotator cuff tear[27]. These genes have suspected roles in inflammation and angiogenesis. Additional genes identified have known roles in mediating cytokine expression, neutrophil and macrophage activation, and response to oxidative stress[28]; however, none is specific to the tendon injury and remodelling. Currently, the exact role of genetics in the development of degenerative rotator cuff disease is unknown. Nevertheless, an increasing body of evidence supports a genetic predisposition in some patients. In addition, sex and ethnicity are not consistently identified as risk factors for developing degenerative rotator cuff disease.

Comorbidities. Several disease conditions have been postulated to have a role in the development and progression of rotator cuff disease, and subsequently, may influence healing rates following surgical repair. These conditions include type 2 diabetes mellitus, hyperlipidaemia, sex hormone deficiency, obesity, smoking, hypertension, gout, connective tissue diseases and depression[23,29–33]. Diabetes mellitus promotes the development of tendinopathy in several areas, including the rotator cuff and Achilles tendon, perhaps owing to altered neural, vascular and immune responses to tissue remodelling[3]. Samples of torn rotator cuff tendons from patients with diabetes mellitus show higher expression of matrix metalloproteinases, such as MMP2, and higher expression of inflammatory proteins (IL-6) than samples from individuals without diabetes[34]. Studies have demonstrated that diabetes mellitus is a definite risk factor for impaired healing after rotator cuff surgery, and those patients with a lower HbA_{1c} (<7%) in the postoperative period have lower retear rates than patients with higher HbA_{1c} (>7%), suggesting an important role of diabetes mellitus in controlling tendon to bone healing[35,36]. Evidence also shows that there is an association between oestrogen deficiency in women and testosterone deficiency in men and outcomes following surgery for a rotator cuff tear[37]. Similarly, in an insurance database study, women with oestrogen deficiency were 48% more likely and men with testosterone deficiency were 89% more likely than age-matched controls to undergo rotator cuff repair surgery[38]. The exact mechanism of hormone deficiencies and their contribution to rotator cuff tears, at the cellular level, have not been elucidated at this point.

Physical activity and occupation. The role of physical activity in the development of rotator cuff disease is debated. Studies in rats have shown that excessive physical activity promotes supraspinatus tendinopathy. The changes induced in the tendon include increased tendon hypertrophy and decreased elasticity and were associated with a combination of intrinsic and extrinsic factors (compression from the coracoacromial arch)[39,40]. By contrast, one study failed to show an association between the level of overhead physical activity or occupational demands with tear progression in a cohort of patients with

Box 1

Classification of rotator cuff tears

Tears are classified based on their size (partial or complete), and several classification systems are used. Most commonly, partial tears are classified based on the amount of tearing off the footprint (Ellman classification) as seen on MRI. Full thickness tears are usually classified with the Codman classification based on tear size in the anterior–posterior dimension. Although these classifications lack high reproducibility, the Codman classification is predictive of outcome after rotator cuff repair, and helps guide treatment decisions. The Goutallier classification is utilized to determine the degree of fatty infiltration within the rotator cuff, and is assessed on sagittal views on MRI.

Partial-thickness tears — Ellman classification[301]

- Grade 1: <3 mm (<25% thickness)
- Grade 2: 3–6 mm (25–50% thickness)
- Grade 3: >6 mm (>50% thickness)
- Location: A, articular sided; B, bursal sided; C, intratendinous

Full-thickness tears — Codman classification (tear size in anterior to posterior direction)[302]

- Small: 0–1 cm
- Medium: 1–3 cm
- Large: 3–5 cm
- Massive: >5 cm

Fatty infiltration — Goutallier classification[160]

- Normal: score 0
- Fatty streaks: score 1
- More muscle than fat: score 2
- Equal fat and muscle: score 3
- More fat than muscle: score 4

asymptomatic tears[41]. For degenerative tears, evidence shows that activity tear development is linked to hand dominance, with higher likelihood of a symptomatic tear in the dominant shoulder than the non-dominant shoulder[13,41–43]. Occupational demands might play a part in rotator cuff tear development; for example, studies have identified several occupational exposure risk factors, such as repetitive arm elevation, heavy lifting and use of vibrating tools, that are associated with rotator cuff tears[44–48]. However, the exact duration and type of exposure that constitute a risk is unknown. A study in a population of >250,000 individuals (UK Biobank) showed a correlation between self-reported manual labour and the need for rotator cuff surgery compared with controls, particularly when the occupational exposure lasted >10 years[49].

Natural history

Although, the greatest risk factor for rotator cuff tear development is age, time is the greatest risk factor for tear progression. The risk of tear enlargement is greater in full-thickness tears than partial-thickness tears[5,43,50]. Although smoking, obesity, diabetes and hyperlipidaemia have been linked to rotator cuff disease, no studies have examined the effects of these conditions on the natural history or progression of rotator cuff disease. The role of scapular morphology, specifically the acromion, in the development of and the progression of degenerative rotator cuff tears is debated. For example, in one study, the critical shoulder angle of patients with an asymptomatic rotator cuff tear was larger than in control patients with normal rotator cuffs but was not associated with tear size or the risk of tear enlargement (median time to enlargement of 3.3 years)[51]. Other studies, including a meta-analysis, demonstrated considerable variability in the relationship between critical shoulder angle and the presence of rotator cuff tears, suggesting that it may only be a factor in some patients[52].

The typical site of initiation of a rotator cuff tear is between 13 mm and 17 mm posterior to the biceps tendon within the rotator crescent[16,53]. The rotator crescent is a relatively hypovascular area of the posterior cuff that is protected to some degree biomechanically by the thick rotator cable, which spans from the anterior edge of the supraspinatus to the inferior infraspinatus[54–56]. Approximately 30% of full-thickness tears, regardless of tear size, involve the anterior cable tissue adjacent to the biceps tendon, and only 3% of small full-thickness tears (≤10 mm) involve this area[53,57]. Longitudinal studies have shown that tear enlargement within the rotator crescent is common in the anterior and posterior directions[4]. Rotator cuff tear location mapping has shown that anterior cable disruption is strongly associated with supraspinatus muscle degeneration[16,58].

Pain is an important clinical indicator of tear size progression over time with the tear width and amount of retraction from the bone increasing. Much of the research examining tear progression has been performed in asymptomatic shoulders by identifying painless tears in patients presenting with a painful cuff tear in the opposite shoulder. Clinically, most patients in whom the tear progressed had an increased risk of developing pain[59]. In a large study of 224 shoulders in patients with asymptomatic tears in one shoulder and a contralateral painful rotator cuff tear, tear progression was found in 49% of asymptomatic shoulders by ultrasonography, with a median time to enlargement of 2.8 years[5]. In this study, the risk of tear enlargement for full-thickness tears was significantly greater than for partial-thickness tears and control shoulders. Overall, 46% of originally asymptomatic shoulders developed pain at a median of 2.6 years. A subsequent study involving 227 shoulders in patients aged 65 years or younger demonstrated continued tear progression over an average follow up of 7.1 years[43]. Overall, 60% of tears enlarged during the 7-year study period. The risks of enlargement of a full-thickness tear at 2 years, 5 years and 8 years were 26%, 58% and 80%, respectively. Approximately 57% of the cohort developed pain, which was strongly linked to tear enlargement. The presence and progression of degeneration of the supraspinatus and infraspinatus muscles were linked to absolute tear size and tear enlargement during follow-up[43].

Clinical evidence strongly suggests that symptomatic degenerative full-thickness rotator cuff tears do not heal, and most tears are at risk of slow progression over time. Tear progression can be defined as tear enlargement or progression of muscle degeneration – both of which have implications on healing potential following surgical repair. Multiple studies have demonstrated that painful tears will enlarge in size, especially over a period of 18 months or more, but the amount of tear enlargement is relatively low[50,60]. For example, in 49 patients with a symptomatic full-thickness rotator cuff tear, the average tear size increase was <1 cm, and progression of muscle degeneration was seen in <50% of patients[59].

Rotator cuff muscle degeneration refers to the development of muscle atrophy and fatty cell infiltration into the muscle. Rotator cuff muscle degeneration is almost exclusive to full-thickness rotator cuff tears[16,57]. In one study, tears that enlarged had more than twice the risk of progression of muscle degeneration than stable tears[61]. Additionally, when tear progression led to disruption of the anterior cable or when the extent of tear enlargement was big, the risk of progression of muscle degeneration increased over time after adjusting for covariates[16,61].

Mechanisms/pathophysiology

Rotator cuff tears represent a spectrum of disease, from impingement, tendinopathy, to partial-thickness tears and to full-thickness tears of varying sizes (Fig. 2). Impingement (originally named after the idea that the acromion impinges on the rotator cuff[62]) occurs when the bursa above the rotator cuff is inflamed as a consequence of altered kinematics of the shoulder girdle. When the larger muscles (deltoid) over-compensate due to rotator cuff dysfunction, the rotator cuff cannot function as an effective force couple, resulting in the humeral head elevating rather than depressing during shoulder motion[63,64]. This altered movement pattern increases inflammation within the rotator cuff bursa above the tendon, leading to pain with motion and overhead activity, and pain during sleep. Although imaging findings are normal in patients with mild impingement, increased fluid signal on ultrasonography or MRI above the rotator cuff is a key indication of active impingement. Studies have suggested that the bursa is a source of active healing of the cuff, by stimulating inflammatory cells and factors that promote healing[65–67]. The bursal cells display mesenchymal markers of stemness, including CD73 and CD90, and, in experimental models of bursa–tendon crosstalk, the bursa has upregulated markers of extracellular matrix production (TGFβ), immune cell signalling and vascular signalling including PDGFRβ[68].

The exact mechanisms of how rotator cuff injury progresses from tendinopathy to partial-thickness tears and to full-thickness tears is yet to be fully understood. In addition, the inconsistent terminology commonly used even among orthopaedic surgeons can be confusing and misleading to patients and providers alike[69,70]. Patients who present with new-onset pain, from a purely biological viewpoint, might have well-established histopathological changes. Why a biologically long-standing condition suddenly manifests itself in an acute fashion is still unclear.

The present scientific evidence suggests that the initial lesion of tendinopathy is a failed healing response to microtrauma, and the role of inflammation in these conditions has been re-evaluated and is thought to be an important contributor[71,72] (Fig. 3). In the development of tendinopathy of the rotator cuff, an increase in inflammatory cells and production of pro-inflammatory cytokines from tenocytes are thought to have a role[3,73]. Animal models of tendinopathy show increased numbers of macrophages and mast cells within the injured tendon[74]. In response to altered mechanical load or tissue injury, tenocytes and immune cells within the tendon release pro-inflammatory cytokines, including TNF, IL-6 and IL-1β. IL-17A has been found to be upregulated in patients with a rotator cuff tear[75]. IL-17A was expressed in various inflammatory cells within rotator cuff tendon, and tenocytes that were treated with IL-17A had increased production of pro-inflammatory cytokines, and increased expression of apoptosis-related factors[75]. The role of IL-17A is notable given the availability of anti-IL-17A monoclonal antibodies (secukinumab and ixekizumab) that have been evaluated for their role in treating tendinopathy[3].

In most patients, partial-thickness tears and full-thickness tears are hypothesized to be the result of the tendinopathy process over a period of many years. Histologically, tendinopathy demonstrates altered collagen organization with increased inflammatory tissue with decreased vascularity, which, for as-yet unidentified reasons, may not necessarily cause symptoms even as tendinopathy progresses into partial-thickness and full-thickness tears. The severity of tear as well as the extent of tendinopathy do not correlate with patient symptoms, which highlights the complex relationship between degeneration, pain development and pain perception at the central nervous system level. An upregulation of the glutamatergic system has been observed in patients with rotator cuff tendinopathy, with localization of glutamate to tenocytes with glutamate receptors on macrophages[76].

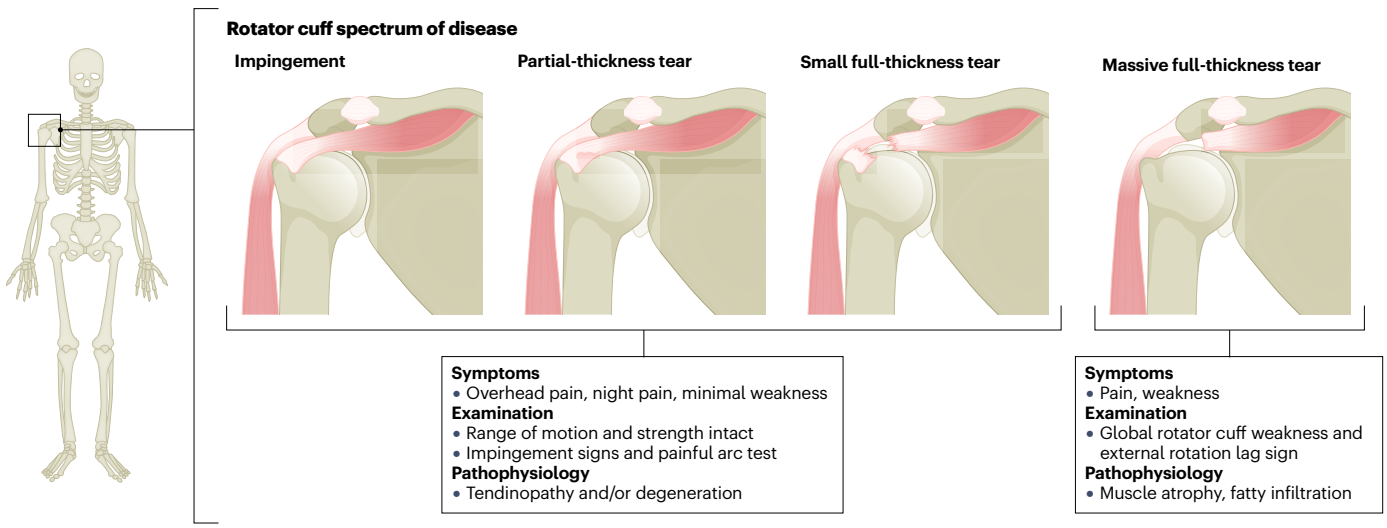

Fig. 2 | Representative pathology and functional differences in rotator cuff pathology. Impingement, partial-thickness and small full-thickness tears present with similar symptoms, with pain on overhead activity, pain at night and variable findings on clinical examination. Patients with larger and massive tears will have lost their force couple and have difficulty elevating their arm, and are more likely to have a positive external rotation lag test than patients with small tears.

Box 2

Risk factors for rotator cuff disease and progression

Non-modifiable risk factors

- Age
- History of contralateral rotator cuff tear
- Genetics
- Familial association
- Single nucleotide variants (apoptosis-related genes)
- Genome-wide association studies (*STK24* upregulation; *SAT1* and *UBED3* downregulation)
- Hand dominance
- Scapular morphology

Modifiable risk factors

- Diabetes mellitus
- Smoking
- Hyperlipidaemia
- BMI
- Hypertension
- Work factors
- High dynamic strength
- Whole-body vibration
- Heavy lifting

Risk factors for tear progression

- Increasing age
- Increasing time from diagnosis
- Increasing tear size (full thickness > partial thickness)
- Location of tear (through rotator cuff cable)

Further, other nociceptive mediators such as mGLuR2 and GluK1 are also upregulated in patients with tendinopathy[76]. Interestingly, tenocytes exposed to glutamate in vitro show decreased cell viability and decreased collagen gene expression[77], providing a possible link between pain and tendon degeneration.

Tendon degeneration

The cellular and molecular pathophysiology of degenerative tendinopathy is highly complex and is only partially understood. A myriad of predisposing factors, including patient-specific factors such as metabolic disorders (that is, hypercholesterolaemia, hyperglycaemia), mechanical overuse and repetitive microtrauma, drug exposure and ischaemia contribute to profound structural changes within the tendon[3]. Both animal-based and clinical studies have demonstrated that activation of secondary inflammatory pathways and oxidative stress in tendon tissue promote tenocyte apoptosis, fibrosis and disorganization of the extracellular matrix and, in some cases, heterotopic ossification (a condition in which bone tissue develops in soft tissue)[28,78,79]. Importantly, chronic tears are the result of consistent tendon abnormalities in the tendon tissue that has been degenerated over a long time. Studies have demonstrated tissue metaplasia, tenocyte apoptosis and reduced regenerative properties of tendon-derived stem cells in tendinopathic tendons, possibly secondary to inflammation and abnormal oxidative stresses[80]. Anti-oxidative and anti-inflammatory therapies that mitigate or suppress these pathways might have therapeutic benefit by altering the natural history of tendinopathy in these settings.

Oxidative stress. Oxidative stress activates signalling pathways that generate reactive oxygen species, which induce inflammation and in excessive quantities, damage cells, lipids, proteins and even DNA[81,82]. Clinical studies have shown increased levels of serum hydroperoxides in tendinopathic tendon tissue and increased concentrations of inflammatory proteins in the synovium and tendon in rotator cuff tears[28]. In animal models, increased mechanical loading and tendon overuse increased the plasma total oxidant status and circulating pro-inflammatory cytokines[79]. Multiple pathways are likely to be involved, and activation of the mTOR pathway[6], resulting in tissue metaplasia and impaired tenogenesis of tendon-derived stem cells[83], may have a major role in tendon degeneration and impaired tendon healing. Interestingly, mTOR is also a central regulator of muscle atrophy; hence, targeting this pathway may serve a dual role in future treatment strategies[84].

Obesity, diabetes mellitus or hypercholesterolaemia further predispose to a pro-inflammatory environment and increase the risk for degenerative tendinopathy. In individuals with comorbidities, reactive oxidative species are increased in these settings, triggering tenocyte apoptosis, fibrosis and tissue metaplasia via mTOR, nicotinamide dinucleotide phosphate oxidase (NOX) and AKT/FOXO1 pathways[82,85]. Drugs such as fluoroquinolones or local anaesthetics such as bupivacaine also predispose to tendinopathy, probably by altering mitochondrial membrane permeability and/or generating reactive oxygen species in cells, thereby inducing oxidative stress and a catabolic, pro-inflammatory response[86,87].

Accordingly, anti-oxidants that reduce the production of reactive oxidative species or drugs such as rapamycin, which inhibit downstream pathways (for example, mTOR), are being actively investigated for managing symptomatic tendinopathy[6]. Studies examining natural anti-oxidants such as curcumin, eugenol and flavonoids, are ongoing[80,88]. Well-designed clinical studies assessing the efficacy of these therapies in symptomatic patients are warranted.

Muscle quality

Muscle quality, defined by the development of muscle atrophy and fatty infiltration, has been implicated as a key factor affecting the outcomes of rotator cuff injury and repair (Fig. 3). Muscle atrophy, a likely consequence of mechanical unloading of the tendon and fatty infiltration, which seems to be chronic resulting from alterations in innervation, affects rotator cuff treatment outcomes. Patients with greater muscle atrophy and increased fatty infiltration are at higher risk of retear after surgery, and worse clinical outcomes than those with less muscle atrophy, even with a technically successful repair[7,89].

Muscle atrophy. Atrophy is defined as the loss of muscle mass, with a physiological shift from protein synthesis to protein degradation[90]. Atrophy is an independent factor that predicts outcomes after rotator cuff repair. The degree of atrophy is used in combination with fatty infiltration and the amount of tendon retraction to gauge the 'repairability' of a rotator cuff tear. Full-thickness rotator cuff tears result in alterations in mechanical load to the muscle–tendon unit, which negatively affect key protein activation, including AKT and mTOR, and alter the expression of atrophy-related genes (atrogenes), such as *MuRF1*

and *ATROGIN1* (refs. 91–93). These findings have highlighted the shift from protein synthesis to autophagy, as well as increased proteasomal activity and atrophy of individual muscle fibres[84,94]. The central regulators of atrophy are yet to be defined. NF-κB is a transcription factor thought to be a key mediator of muscle atrophy in several pathological states, including cancer cachexia and ageing[95]. However, the role of NF-κB in rotator cuff tear-induced atrophy seems to be minimal, as gain-of-function and loss-of-function studies have shown little difference in muscle size in a mouse model of full thickness rotator cuff tears[90]. Relatively few studies have evaluated the role of the primary muscle stem cell, the satellite cell, in the maintenance of muscle size. In animal models of full-thickness rotator cuff tears, the number of satellite cells remained constant[96], suggesting that the presence of a tear does not cause depletion of this important muscle stem cell.

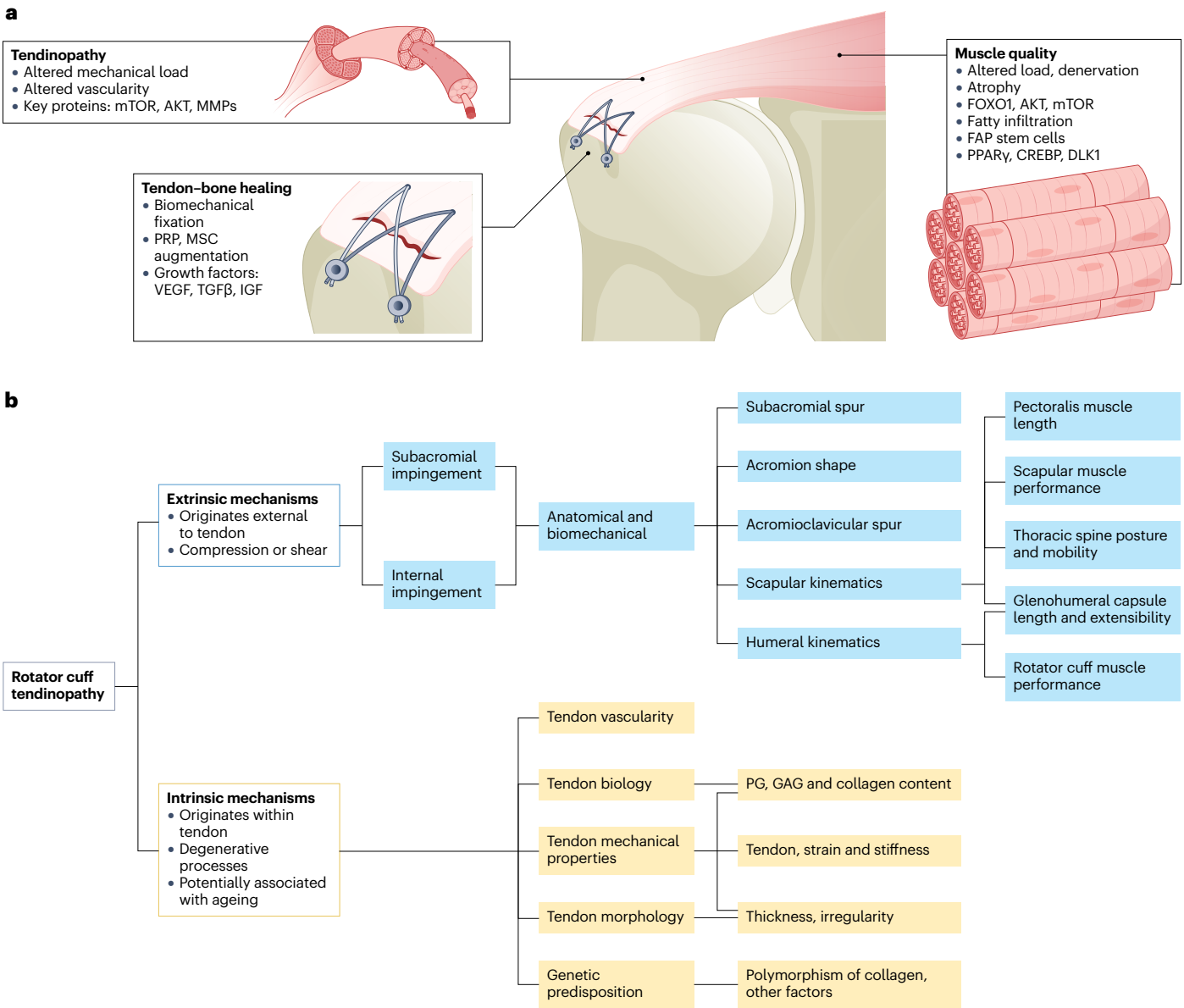

Fig. 3 | Muscle and tendon biology of the rotator cuff. a, Tendinopathy is caused by a variety of factors including overuse, mechanical load alterations and changes in vascularity. Muscle degeneration, which is due to muscle atrophy and fatty infiltration, is typically seen in the setting of a large rotator cuff tear. Tendon–bone healing is primarily influenced by the biomechanical repair strategy, and treatments such as platelet-rich plasma (PRP) and mesenchymal stem cell (MSC) delivery have been shown to improve retear rates, but not to affect clinical outcomes. **b**, The pathogenesis of rotator cuff is complicated, with both extrinsic and intrinsic factors contributing to tendon degeneration. Extrinsic factors, including anatomical changes such as acromial bone spurs and degeneration of the acromioclavicular joint, cause impingement on the rotator cuff tendon. Alterations in shoulder kinematics similarly cause extrinsic load alterations as well as changes in muscle forces across the shoulder joint. Intrinsic degeneration is due, in part, to alterations in collagen structure and orientation, changes in vascularity, and probably genetic factors that predispose some patients towards tendinopathy. These changes result in increased tendon stiffness and loss of the intrinsic structure of the tendon. FAP, fibroadipoprogenitor.

Similarly, in human studies, satellite cell numbers are not diminished, but their ability to contribute to muscle size and regeneration may be limited in the setting of aged rotator cuff tissue[97–101].

Fatty infiltration. Fatty infiltration (that is, infiltration of fat from the surrounding tissue[102]) has emerged as an important biological concept involved in muscle degeneration across many conditions, including ageing, low back pain and muscular dystrophy. The presence of fatty infiltration worsens the quality of muscle, as the amount of tissue that can develop force decreases with a concomitant alteration in the biomechanical properties of the tissue[103]. Several animal studies and human studies have demonstrated the importance of FAPs in the development of fatty infiltration[9]. These cells have a central role in the regulation of muscle degeneration; for example, in muscular dystrophy, amyotrophic lateral sclerosis and ageing[104–111]. In animal models, FAPs have been shown to proliferate at the time of rotator cuff injury and directly contribute to the development of fatty infiltration through expression of white fat-associated genes including *PPARG*, *CREBP* and other fat-related genes[84,96,112]. Fatty infiltration can be decreased through inhibition signalling molecules, such as TGFβ, retinoic acid and PPARγ, which probably work through modulating the response of FAPs to injury[113–116]. In human studies, FAPs proliferate at the time of rotator cuff injury, and increase in number as tear size progresses[8] and express several fat-related and fibrosis-related genes[117–119]. Non-biased transcriptomic studies have shown that FAPs isolated from partial-thickness tears are less likely to express markers of adipogenesis and fibrosis than FAPs from full-thickness tears. Adipogenic commitment is driven by downregulation of DLK1, which is seen in FAPs from patients with full-thickness tears[120]. Importantly, FAPs also seem to have pro-regenerative capabilities in vitro when stimulated with pharmacological agents, which may be utilized to improve muscle quality at the time of and after rotator cuff repair[121–124].

Tendon healing after repair

Tendon–bone healing, a highly complex process, is crucial to the success of rotator cuff repair; yet, the mechanism underlying this process remains a critical unmet need in this field. The native enthesis is a highly organized structure with remarkable architecture designed to transmit loads from muscle through unmineralized and mineralized fibrocartilage to bone[125,126]. Re-establishment of the rotator cuff tendon to bone interface does not recapitulate the organized anatomy or structure of the native enthesis. Lineage tracing studies suggest that even in acute reattachment, the native enthesis is replaced with scar-forming cells leading rather to a mechanically inferior attachment[127].

Healing at the enthesis follows the typical reparative cascade of inflammation, proliferation and remodelling[128]. Pro-inflammatory cytokines released by platelets from the clot recruit macrophages, neutrophils and tendon-derived cells to initiate the repair response. The proliferative phase of collagen and extracellular matrix deposition by recruited fibroblasts results in an increase in cellularity and collagen deposition. During this time, there is also an increase in vascularity. This is followed by remodelling, in which there is a subsequent reduction of cellularity and vascularity that is accompanied by a shift from type III collagen to type I collagen, and morphological reorganization and realignment of the collagen to respond to mechanical loads.

Molecular mediators. A myriad of cytokines, including IGFs, VEGF, PDGF and members of the TGFβ family, regulate the production of collagen and extracellular matrix during the reparative and remodelling phases[129,130]. These cytokines induce paracrine and autocrine responses that affect fibroblast migration, angiogenesis, collagen production and matrix metalloproteinase activity[131]. Variations in both the quantity and temporal expression of these cytokines markedly affect the healing response at the enthesis, including the potential to shift from fibrosis and scar formation to tissue regeneration. Accordingly, there is a tremendous focus on augmenting tendon–bone healing through modulation of these growth factors or through a paracrine effect of secretomes associated with local stem cell recruitment or delivery[131–133].

Diagnosis, screening and prevention

Clinical presentation

Patients with a symptomatic rotator cuff tear typically present at ~50–70 years of age, with pain at night that keeps them from sleeping, pain with overhead activity such has reaching a high shelf, or a subjective feeling of shoulder girdle weakness. Despite a clear pathophysiological progression from tendinopathy to partial-thickness tears to full-thickness tears, symptom severity does not necessarily correlate with histopathological severity (Fig. 4).

Diagnosis

The diagnosis of a rotator cuff tear is based on the location of pain (typically along the lateral shoulder), timing of pain (nocturnal pain and pain with overhead activities) and key physical examination findings. However, the location and type of pain described by patients are often non-specific and only beneficial to a certain extent. Understanding the symptoms of rotator cuff pathology in comparison with other common shoulder ailments, especially frozen shoulder and glenohumeral arthritis, is important. The differential diagnosis of rotator cuff tears is broad and should include degenerative conditions of the shoulder girdle and the cervical spine (Table 1). Physical examination of the patients suspected to have rotator cuff pathology should focus on the integrity and functioning of the rotator cuff and periscapular muscles. Despite advances in imaging techniques, history and physical examination remain the primary diagnostic tools and determinants of management.

Physical examination. Physical examination must begin by exposing both shoulder girdles to assess their symmetry. Muscle atrophy, in the infraspinatus or supraspinatus fossae, is common in patients with chronic, larger rotator cuff tears[134]. The acromioclavicular joint, anterior capsule, coracoid process, posterior capsule, bicipital groove and acromion are palpated for tenderness[135]. Most patients with rotator cuff tears will not report tenderness in these areas, but they should be assessed for concomitant pathology.

A comprehensive assessment of shoulder range of motion is performed. The cervical spine should be examined to rule out pain coming primarily from a spine condition. Cervical spine pathology typically presents with a history of radiating pain down past the shoulder and into the hand, or associated numbness and tingling in a neurological distribution. During examination of the shoulder, forward flexion, abduction, internal rotation and external rotation are evaluated from the adducted position (that is, with the patient's arm at the side). Internal and external rotation should also be performed with the shoulder abducted to 90° with the elbow flexed to 90° to check for early arthritis and frozen shoulder – both conditions cause loss of active and passive motion[136].

The strength of the rotator cuff muscle is also assessed at this step. Abduction strength is tested with the patient's arms abducted at 90°

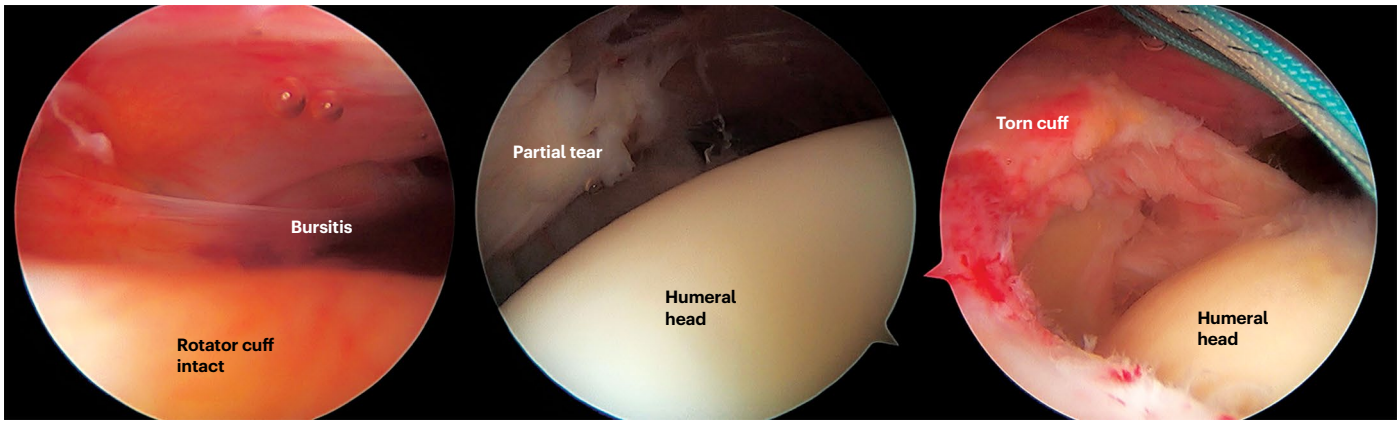

Fig. 4 | Surgical anatomy of rotator cuff tears. Arthroscopic images of rotator cuff impingement (part **a**), partial-thickness tears (part **b**) and full-thickness tears (part **c**). In impingement, inflammatory tissue is present above the intact rotator cuff, with increased vascularity and tissue in the subacromial space. In partial-thickness tears, there is fraying of the rotator cuff, but the attachment of the tendon to the greater tuberosity is largely intact. In full-thickness rotator cuff tears, the rotator cuff is detached from the humeral head. In this example, the tear is large with retraction of the rotator cuff to the glenoid rim.

and forward-flexed at 30° to be in the plane of the supraspinatus[137]. Weakness in this position (measured manually with applied downward pressure) can be indicative of a supraspinatus tear. External rotation strength is tested with the patient's arm adducted and the elbow flexed to 90°. Weakness with external rotation can be indicative of a tear of the infraspinatus and/or teres minor, which is almost always accompanied by a supraspinatus tear that has extended posteriorly. The patient can also be assessed for a painful arc – the patient must raise the arms above the head and bring the arms down slowly to the sides. In a positive test, the patient reports pain during the 120° movement down to the 40° angle. This test is the most sensitive in patients with a rotator cuff problem; however, the test cannot differentiate between tendinopathy, partial-thickness tear and full-thickness tear[138].

Physical examination tests. Although several well-described tests can aid the examiner in diagnosing rotator cuff pathology. These tests lack high sensitivity and specificity and, therefore, must be used in conjunction with history and imaging to establish an accurate diagnosis. The Neer test is performed with the examiner standing behind the patient with the affected arm passively elevated with the examiner's hand stabilizing the scapula. Pain at maximal forward flexion is often indicative of rotator cuff pathology[137,139]. In the Hawkins–Kennedy test, the affected arm is passively elevated to 90° of forward flexion and the elbow is placed at 90° of flexion in the neutral position. The forearm is then turned into internal rotation, which brings the greater tuberosity into contact with the undersurface of the acromion. Pain with internal rotation is suggestive of rotator cuff pathology[137,140]. The Jobe test is performed to assess the strength of the supraspinatus. The patient places the arm at 90° of abduction and 30° of flexion in the plane of the scapula. Shoulder elevation is manually resisted by the examiner. Pain or weakness denotes a positive test[140,141]. Furthermore, the drop arm test can also be used to assess the supraspinatus muscle. The patient's arm is passively abducted to 90° and the patient then slowly lowers the straight arm to the side (adducted position). Inability to control the descent of the arm or pain reported during this manoeuvre constitutes a positive test[138–140].

Several tests are also available to assess the subscapularis muscle and tendon. The shoulder must be placed in an internally rotated position prior to testing to eliminate the strength of the pectoralis. The lift-off test (Gerber test) is performed by placing the arm in an internal rotated position behind the patient's back[138]. The dorsum of the hand is placed at the base of the lumbar spine and the patient is asked to lift the hand off the back and hold the position. The strength of the manoeuvre is assessed by the examiner by applying counter-pressure to the hand. An inability to lift the hand off the back or inability to resist the examiner's counter-pressure represents a positive test[140,141]. The belly press test evaluates subscapularis function: in a standing or seated position, the patient's arm is abducted ~20–30° with the arm internally rotated and elbow flexed to 90°. The patient is instructed to press the palm of the hand into the abdomen while keeping the ipsilateral elbow in the abducted starting position. The patient not being able to perform the manoeuvre or the elbow falling to the patient's side during the attempted press indicates a positive test[140,142,143].

No single test is diagnostically accurate, but the combination of manoeuvres, and correlation with symptoms, facilitates an accurate diagnosis of rotator cuff pathology. However, distinguishing the spectrum of impingement to partial-thickness to small full-thickness tears remains challenging. Nevertheless, large tears and those with loss of the force couple from tears that extend through the rotator cuff cable[55] are readily diagnosed owing to profound weakness of the shoulder (pseudoparesis) and by a positive external rotation lag sign[138,144].

Radiography. Imaging is an important diagnostic tool for evaluating the severity of rotator cuff pathology. Multiple imaging modalities allow non-invasive diagnosis of rotator cuff tears and can provide key information to determine the most appropriate and effective treatment options. Imaging evaluation should begin with plain radiographs of the shoulder, as they are inexpensive and accessible, and can provide information regarding acute bony injury or confirm the presence of concomitant degenerative joint disease, which influences initial management. Key findings from imaging include the degree of rotator cuff tear arthropathy[145]; degenerative or proliferative changes at the

Table 1 | Differential diagnosis of rotator cuff pathology

Diagnosis	Clinical symptoms or key physical examination findings
Rotator cuff degeneration	Impingement signs Neer test (sensitivity 72–78%, specificity 58–60%) Hawkins–Kennedy test (specificity 79–92%, sensitivity 25–57%) Painful arc test (positive likelihood ratio 3.7)
Supraspinatus tear	Painful arc test (positive likelihood ratio 3.7) Jobe test (sensitivity 69–88%, specificity 30–62%) Drop arm test (sensitivity 8–12%, specificity 92–100%)
Subscapularis tear	Pain or weakness with lift-off test (sensitivity 25–100%, specificity 50–94%) Pain or weakness with belly press test (sensitivity 34–73%, specificity 72–96%)
Large rotator cuff tears	External rotation lag sign (positive likelihood ratio 7.6) Weakness with muscle testing (all groups)
Other common shoulder pathologies	
Frozen shoulder	Limited active and passive range of motion (no radiographic signs of glenohumeral arthritis)
Glenohumeral arthritis	Limited active and passive range of motion (radiographic signs of glenohumeral arthritis)
SLAP tear	O'Brien test
Biceps tendonitis	Painful at bicipital groove Yergason test Speed test
AC joint degeneration	Tenderness at AC joint Cross-body test
Cervical spine degeneration	Radiating pain past elbow Spurling test

AC, acromioclavicular; SLAP, superior labrum anterior posterior.

greater tuberosity and at the undersurface of the acromion[146,147] and signs of osteoarthritis[148,149]. An acromiohumeral interval of <6 mm suggests a chronic full-thickness rotator cuff tear[150]. Radiographs can also effectively diagnose conditions such as greater tuberosity fractures, calcific tendinopathy and shoulder osteoarthritis, which may have overlapping symptoms with rotator cuff disease but different treatment pathways[148,151–153].

MRI. MRI offers a comprehensive three-dimensional evaluation of the rotator cuff and has high diagnostic performance in detecting partial-thickness and full-thickness rotator cuff tears, with sensitivity and specificity values ranging from 0.8 to 0.97 (refs. 154,155). Images from MRI can provide an accurate assessment of clinically relevant measurements that help predict the likely success of surgical repair, including tear size[156] and tendon retraction[157], and depict the presence of associated injuries of the acromioclavicular joint, labrum and glenohumeral cartilage[158]. A fat-sensitive sagittal–oblique sequence is essential for evaluating the rotator cuff muscle quality, which is most commonly performed clinically with the Fuchs modification of the Goutallier classification[159]. The Goutallier classification grades muscle quality from 0 to 4: 0 indicates normal muscle with no fat, 1 indicates streaks of fat in the muscle, 2 indicates more muscle than fat, 3 indicates equal proportions of muscle and fat, and 4 indicates more fat than muscle in the expected muscle location[159]. Muscle quality, especially of the infraspinatus, is predictive of surgical outcomes after rotator cuff repair[160–162]. The Goutallier classification impacts clinical decisions, although the reproducibility of this system is moderate at best[163–165]. Advanced MRI techniques, such as IDEAL MRI and Dixon fat–water separation sequences, can allow a more precise measurement of intramuscular fat that allows improved treatment recommendations compared with findings from conventional MRI[89,166–169]. Information obtained from preoperative MRI can be utilized in scoring systems, such as the rotator cuff healing index, which offer insight into the likelihood of success after surgical treatment[170]. Magnetic resonance arthrography has excellent diagnostic performance and is an additional option for imaging, although the addition of intra-articular contrast material is often not necessary for the routine evaluation of rotator cuff tears[155,171]. In areas with limited MRI availability, availability of arthroscopic surgical resources might also be limited, making overall diagnosis and treatment of rotator cuff pathology very challenging.

CT. CT is less frequently utilized than other imaging modalities for the diagnosis of rotator cuff tears. The Goutallier classification was originally developed based on CT imaging. Although CT can provide an evaluation of muscle quality, a detailed analysis of soft tissue employing a CT scan is limited[161]. For patients who do not have access to MRI, a CT arthrogram can be an option to evaluate the rotator cuff; extension of contrast material into the subacromial space indicates a full-thickness rotator cuff tear[172].

Ultrasonography. Ultrasonography can offer excellent information regarding all clinically relevant aspects of rotator cuff injuries, while also being low-cost, portable and more comfortable for patients than MRI[173–175]. Ultrasonography can detect partial-thickness and full-thickness rotator cuff tears, with specificity ranging from 0.77 to 0.98 (refs. 155,176,177). Ultrasonography can be utilized to determine rotator cuff tear size, retraction and muscle quality[16,178]. Although ultrasonographic evaluation can be operator-dependent, this modality can be an excellent, low-cost first-line option for evaluating the rotator cuff[173].

Prevention strategies

When developing prevention strategies for the development of rotator cuff tears, it is important to understand that not all risk factors are modifiable. However, strategies should minimize not only the development of rotator cuff pathology but also symptoms. Postural training, flexibility programmes and simple strengthening exercises for the shoulder and scapular muscles can be beneficial in improving shoulder health[179]. These strategies might help to minimize the risk of developing poor posture or form, which can lead to compensation and undue pressure on an ageing rotator cuff, leading to injury. However, studies have not shown a clear link between improving posture and minimizing the incidence of cuff tear and, therefore, the benefits of better posture remain theoretical.

Although flexibility and rotator cuff exercises can be beneficial in the prevention of symptoms, studies have shown that excessive repetitive use of the rotator cuff can be detrimental[180]. The repetitive nature of overhead sports is a well-known factor that contributes to rotator cuff symptoms, although how progression to full-thickness tears occurs is unclear. Limiting the time spent engaged in repetitive exercises and activities, careful biomechanical evaluation of performance and a continual emphasis on form are the most effective preventative measures to avoid symptoms arising from a rotator cuff tear.

Smoking cessation programmes are imperative before any surgical intervention to circumvent its negative effect on healing. Chronic

inflammation, which are observed in individuals with diabetes mellitus and obesity can contribute to tendon injury[181]. Although no clear dietary change can prevent rotator cuff tears, following an anti-inflammatory diet (for example, foods that are high in anti-oxidants such as blueberries, almonds and fatty fish) may aid in alleviating pain and inflammation associated with rotator cuff injuries. Further research investigating the role of anti-inflammatory diet is necessary[182]. In animals, vitamin D deficiency may affect the ability of an acutely injured rotator cuff to heal following surgery. Hence, screening for and treating vitamin D deficiency may be beneficial[183]. Evidence shows a possibility of longer duration of symptoms and a worse prognosis in patients with depression and anxiety than in those without. Patients should be screened to identify those with these common pathologies so that they can be counselled to improve outcomes[184].

Management

The goals of management are to reduce pain and enable return to function, including improved sleep. In asymptomatic patients or in those with minimal shoulder symptoms, observation alone might be sufficient. These patients should be made well aware of the risks of progression, with pain serving as a key marker of likely tear progression over time and an indicator warranting evaluation and treatment.

Physical therapy

The predominant treatment modality in patients with symptomatic rotator cuff tendinopathy, or partial-thickness or full-thickness tears is physical therapy. Physical therapy is effective and when successful, results in quicker return to activities and function than surgical treatment[185]. The MOON Shoulder Group followed 381 patients (31–90 years of age; mean age 62 years) with atraumatic full-thickness rotator cuff tears over 2 years, and demonstrated substantial improvements in patient-reported outcomes (PROs) including American Shoulder and Elbow Surgeons (ASES) scores and a reduced rate of surgery after physical therapy[186]. Patients undertook 6–12 weeks of a standardized supervised physical therapy programme focusing on basic rotator cuff strengthening and shoulder mobility, and >70% of the patients demonstrated improvements in PROs and were satisfied with non-operative management. Importantly, belief that physical therapy would improve their symptoms was the most important factor in predicting the success of therapy[187]. Several other randomized studies have shown similar outcomes comparing physical therapy and surgical intervention with short-term and mid-term follow-up[188,189], although long-term PROs may favour surgery in some patients at 10 years after presentation[190]. Even in the setting of massive tears, a deltoid muscle rehabilitation regimen is effective in improving function and pain[191].

The goal of physical therapy is restoration of full, pain-free range of motion, flexibility, muscle balance and scapulothoracic and glenohumeral muscular control and stability. Improving scapular stability, proper neuromuscular control of the shoulder girdle and thoracic posture are essential in a well-designed rotator cuff exercise programme[192,193]. Potential contributing mechanisms to abnormal scapular kinematics include pain, soft-tissue tightness, altered muscle activation or strength imbalances, muscle fatigue and poor thoracic posture[194,195]. Studies have shown tightness of the pectoralis minor and posterior glenohumeral capsular stiffness in relation to abnormal scapular position. Rehabilitation exercises to stretch the posterior cuff and pectoralis minor and reduce upper trapezius activation are recommended to improve soft-tissue tightness and allow optimal scapular motion. For larger tears, physiotherapy should focus on active anterior deltoid strengthening, teres minor strengthening for active external rotation, scapular stability and control exercises, patient education, adaptation, proprioception and a home exercise programme[191].

Medical management

Pharmacotherapy, including medications such as acetaminophen, NSAIDs and corticosteroids, can be used for short-term pain relief in patients with symptomatic rotator cuff tears. If no contraindications exist, acetaminophen is commonly used as the first-line medication and NSAIDs are suggested for intermittent use as a second-line treatment. Oral and topical NSAIDs can effectively relieve shoulder pain secondary to tear if used for a short time period (4–8 weeks)[196,197] and have been shown to be safe preoperatively and postoperatively[198]. The adverse effects of these medications should be taken into consideration when used as long-term treatment.

Subacromial corticosteroid injections (CSIs) are recommended in the inflammatory stage or early stages of rotator cuff tears to reduce pain and improve function in patients with moderate-to-severe pain and in those who failed initial physical therapy and/or oral anti-inflammatory drugs. CSIs can be effective in the short term, especially for small tears, and CSIs in combination with physical therapy can successfully reduce pain and improve function within 6 weeks. This combination can allow some patients to avoid surgery altogether. If not successful after 6 weeks of treatment, the long-term efficacy of CSIs is limited. Importantly, preoperative CSIs may be associated with increased rates of postoperative infections and revision surgery if administered within 1 month of surgery[199–201]. Furthermore, the administration of two or more CSIs the year before surgery substantially increases the risk of subsequent revision rotator cuff surgery[199].

Platelet-rich plasma

Many studies have investigated platelet-rich plasma (PRP) as a potential non-operative treatment for rotator cuff tears and have shown mixed results regarding the effectiveness of these injections. The studies showed reduced pain and improved function in patients with tendinopathy at 6 months with deterioration to baseline levels by 1 year[202]. A meta-analysis in 2023 demonstrated that PRP was equivalent to CSIs in terms of pain relief and function at any given time point[203]. In addition, these studies showed substantial variability in the number of PRP injections, injection volume and platelet concentration. According to the 2019 clinical practice guidelines from the American Academy of Orthopaedic Surgeons, evidence is limited to support the routine use of PRP for treating cuff tendinopathy or partial-thickness tears and, currently, PRP is not indicated for the treatment of full-thickness tears.

Mesenchymal stem cells

The advent of MSCs has opened new potential avenues for therapeutic interventions for rotator cuff tears. This technique involves the injection of MSCs into the rotator cuff tendon or into the subacromial bursa. Studies have shown significant improvements in pain and functional outcomes in patients treated with MSCs compared with placebo, but further research assessing mid-term and long-term outcomes is needed to standardize their use[204]. Moreover, the use of culture-expanded MSCs is not approved by the FDA and, therefore, these cellular treatments are only available in the USA within an Investigational New Drug application or FDA-regulated randomized control trial.

Proper patient counselling and careful patient selection are crucial when considering non-operative management of rotator cuff tears. Educating the patient to understand that non-operative treatment

typically does not result in a complete 'cure' or healing of the tear despite symptom improvement is important. Although conservative management can successfully treat most patients with rotator cuff tears, ~25% of patients progress to need surgical intervention.

Surgical intervention

Subacromial decompression including acromioplasty is a widely performed procedure to treat subacromial impingement syndrome[205,206]. Despite the theoretical advantages of acromioplasty, its role in pain management and/or prevention of progression to rotator cuff tear is still a matter of debate. Several randomized trials found superiority of acromioplasty to exercise therapy alone[207,208]; however, long-term follow-up studies found no significant differences in clinical outcomes[209–213].

All-arthroscopic rotator cuff repair is considered the treatment of choice for rotator cuff tears that fail non-operative management or for acute traumatic rotator cuff tears. However, retear remains an unsolved problem, reported for 10–40% of procedures[214]. Short-term outcomes are favourable regardless of retear; however, in many patients with retear, long-term outcomes are worse than in patients without retear and deteriorate over time[215–217].

To prevent retear, accurate prediction of reparability and healing after repair is important. Predictors of retear can be classified as tear characteristic factors and patient demographic factors. Tear characteristic factors include tear size[170,218–220], fatty infiltration and muscle atrophy[221]. These factors could decrease the elasticity and vitality of the rotator cuff tendon tissues, inhibiting healing after rotator cuff repair[221,222]. Old age, diabetes, osteoporosis, dyslipidaemia, obesity and smoking are demographic risk factor for retear[170,218,222–225]. Using a 15-point scoring system to predict healing after cuff repair[170] (Table 2), retear rate in patients with ≤4 points was 6.0%; however, rates in those with ≥5 and ≥10 points were 55.2% and 86.2%, respectively.

Given the high retear rates, there has been considerable focus on improving the biomechanical and biological construct of the repair. The ideal biomechanical suture configuration for rotator cuff repair requires mechanical stability until tendon-to-bone healing occurs, without excessive tension, which can damage the repaired tendon[226,227]. To achieve this goal, several repair techniques are employed but there is no consensus on the optimal technique, which is likely to depend on tear configuration and so-far-undefined patient-specific factors[228]. Although the biomechanical properties and retear rates of double-row suture bridge repair are better than simple single-row repair[229–231], clinical outcomes according to repair technique are not significantly different[232].

The use of orthobiologics, such as MSCs intraoperatively has shown promising results to decrease retear rates[233]. In a prospective study[234], bone marrow aspirate concentrate augmentation resulted in a 39% decrease in retear rate at 1 year compared with a control group who underwent rotator cuff repair only. For PRP, several studies have shown improved healing rates, particularly in larger tears, but clinical outcomes are not improved by PRP augmentation[235–238]. Although PRP may enable some early mobilization and pain relief, the long-term outcomes are comparable to those following well-performed rotator cuff repair[239,240]. The clinical evidence for the use of PRP in the non-operative management of rotator cuff disorders is inconsistent, making inferences difficult. Furthermore, in one study in patients with rotator cuff tears managed with arthroscopic surgical repair, there was no difference in clinical and imaging outcomes at 10 years follow-up between those receiving and those not receiving PRP injections[241]. The wide range of effectiveness can be related to the types of PRP used and the variability in preparation techniques, cell counts and growth factors available[242]. These differences make it necessary to plan adequately powered appropriately standardized studies with clinically relevant outcome measures.

In patients with an irreparable tear, when retracted tendons cannot be re-attached to the greater or lesser tuberosity without arthritic change of the glenohumeral joint, other treatment options are considered, especially in young, active patients. These include partial repair, superior capsular reconstruction (reconstructing the superior capsule using allograft or autogenic tensor fascia lata), an allogenic or xenogenic patch bridging graft, muscle advancement (releasing the proximal rotator cuff muscle to re-attach to the footprint), tendon transfer, subacromial balloon spacer, and other procedures[243–246]. Results with these diverse treatment strategies are mixed, as expected in small case series with complex conditions.

If the rotator cuff tear is assumed to be irreparable in older patients and/or if accompanied by arthritic change of the glenohumeral joint, reverse shoulder replacement is the primary treatment option[247]. Reverse shoulder arthroplasty reverses normal anatomy, so that the glenoid has the 'ball' side (glenosphere on the glenoid side) articulating with the humeral cup (metal tray with polyethylene insert). This technique has excellent long-term outcomes for irreparable cuff tears and cuff tear arthropathy[247,248]. The 10-year success rate of reverse shoulder arthroplasty is up to 93%, but functional outcomes deteriorate over time, particularly in patients >80 years of age[249–251]. Various complications related to reverse shoulder including scapular acromial notching, instability, infection and glenoid loosening can occur (at rates of 1–5%)[252–257].

An overall algorithm for treatment is presented in Fig. 5. Rotator cuff repairs with concomitant moderate-to-severe glenohumeral osteoarthritis had worse outcomes than rotator cuff tears with mild glenohumeral osteoarthritis[258]. Thus, reverse shoulder arthroplasty in patients with rotator cuff tear with concomitant moderate-to-severe osteoarthritis classified as grade ≥2 using the Samilson–Prieto classification is the treatment of choice, especially in those >65 years old[148,258].

If the degenerative arthritic change is mild (Samilson–Prieto classification grade ≤1)[148], the healing potential of the rotator cuff repair is

Table 2 | 15-point scoring system to predict healing after arthroscopic rotator cuff repair

Factor	Points
Demographics	
Age >70 years	2
Bone mineral density T-score ≤−2.5	2
Level of work activity high	2
Tear characteristics	
Anteroposterior direction tear size >2.5 cm	2
Mediolateral direction tear size (retraction) <1 cm	0
Mediolateral direction tear size (retraction) 1 to <2 cm	1
Mediolateral direction tear size (retraction) 2 to <3 cm	2
Mediolateral direction tear size (retraction) ≥3 cm	4
Infraspinatus fatty infiltration Goutallier grade ≥2	3

Using this algorithm, retear rates of patients with ≤4 points were 6.0%; however, those with ≥5 and ≥10 points were 55.2% and 86.2%, respectively[170].

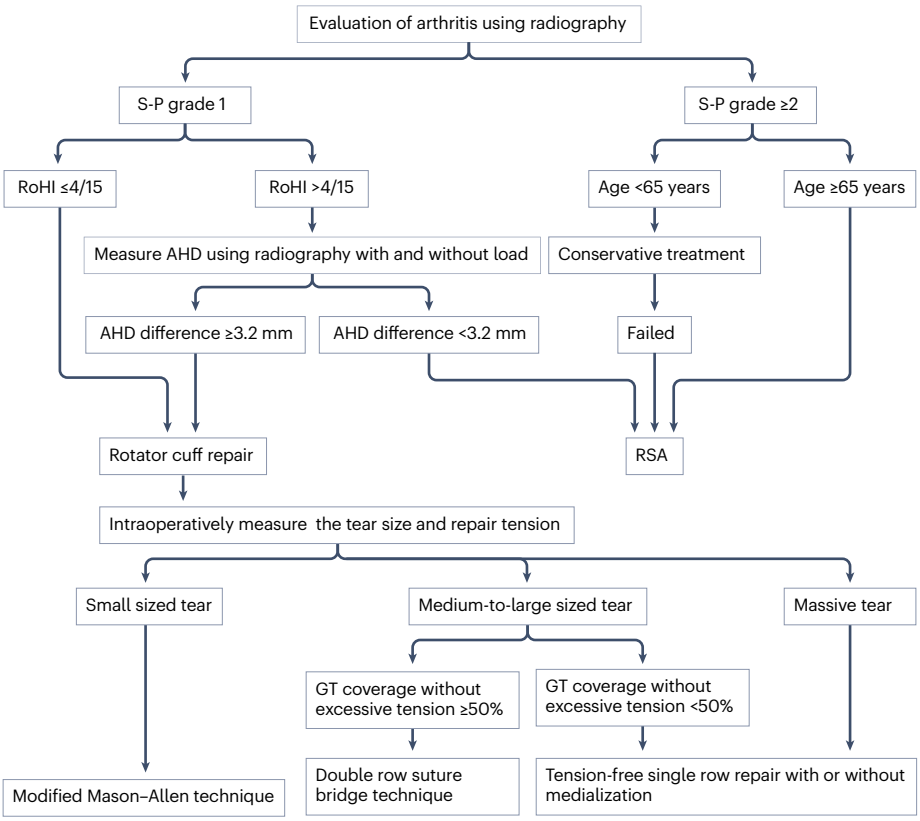

Fig. 5 | Algorithm for rotator cuff tear treatment. Patients with a known rotator cuff tear are evaluated with radiographs. Patients with advanced arthritis (Samilson–Prieto (S-P) grade 2–4) are treated with either conservative management (physical therapy or steroid injections) or reverse shoulder arthroplasty (RSA). In patients with minimal arthritis (S-P grade 1), treatment is determined by the rotator cuff healing index (RoHI)[170]. A score of >5/15 suggests a lower likelihood of healing, and the acromial humeral distance (AHD) is measured as a sign of chronic superior humeral head migration. If the AHD is <3.2 mm, then surgical treatment should be an RSA. In patients with a RoHI score of <5/15, or an AHD of >3.2 mm, a rotator cuff repair is recommended. Small tears can be treated with several options including simple sutures or a modified Mason–Allen repair. For larger tears and massive tears, greater tuberosity (GT) coverage dictates either a double row suture bridge or single row repair to reduce tension on the repair. Irreparable tears can be treated with RSA, tendon transfers or another procedure such as a biceps transfer or balloon arthroplasty.

considered. To predict healing potential, utilization of the aforementioned 15-point scoring system including age, bone mineral density, level of work activity, tear size and fatty infiltration of the infraspinatus might be helpful[170,259] (Table 2). In patients with rotator cuff tear with a score of ≤4, repair should be considered. In patients with a score of >4, X-ray can evaluate whether there is fixed humeral head elevation[260]. If the acromiohumeral elevation is fixed and not reversible, reverse shoulder arthroplasty should be considered as the treatment option.

Quality of life

Rotator cuff tears of all sizes and cuff tear arthropathy can be painful with the potential to compromise motion, strength and function[261,262]. By contrast, structural change to the rotator cuff can be identified in a large proportion of individuals (~60 years of age) who never complain of shoulder pain or loss of function[263]. Hence, the effect of rotator cuff disease on well-being remains difficult to analyse.

Psychosocial and mental health problems are associated with greater symptoms and worse function in patients with symptomatic rotator cuff disease than in patients without mental health issues[33,264,265]. Whether the rotator cuff disease is further disabling because of worse mental coping mechanisms or if the chronicity of rotator cuff disease leads to psychological and mental dysfunction in these individuals remains unclear. Regardless of causation, anxiety, depression and similar disorders seem to negatively impact non-operative and surgical outcomes. In addition, rotator cuff disease is associated with sleep disturbance[266–268], which is common even more than a year after rotator cuff repair[269].

Long-term outcomes

Non-surgical management. Relatively few studies have investigated the long-term quality of life and overall outcomes in patients treated non-operatively for full-thickness rotator cuff tear. For example, in one study that followed 93 patients for five or more years, 25 patients (27%) had undergone surgery at the latest follow-up. Of 63 patients who completed the rotator cuff quality of life (RC-QOL) questionnaire, those treated non-operatively scored 83 out of 100 points and those treated surgically scored 89 out of 100 (ref. 270). Isolated full-thickness supraspinatus tears seem to respond well to non-operative management in the long term, with reasonable overall outcomes and limited progression of fatty infiltration[271]. Tear progression seems to be associated with recurrent or deteriorating symptoms and, therefore, some patients who initially respond well to non-surgical treatment may undergo surgery in the future. In a long-term randomized controlled trial, the non-operative group did not do as well as the surgically repaired group at 10 years, suggesting that, in younger or more active patients, repair may be preferred[190], a concept that was supported in a propensity-matched study[272].

Surgical rotator cuff repair. Several studies have shown substantial improvements in pain, function and quality of life following rotator cuff repair[261,273,274]. Improvements in quality of life after surgery seem to be maintained in the long term[261,275]. Interestingly, and rather perplexing, a large number of patients who became and remained asymptomatic after rotator cuff repair showed evidence of persistent thinning of the repaired site or even structural failure of the rotator cuff repair on

imaging, indicating that the repaired tendons never completely heal despite improvements in pain, motion, function and quality of life[261]. Several long-term studies suggest that healing is important and, if repair integrity is intact, the outcomes at 10–15 years after surgery are excellent[276,277].

Reverse shoulder arthroplasty. Reverse shoulder arthroplasty provides substantial improvements in pain, function and quality of life in many individuals with an irreparable cuff tear, particularly cuff tear arthropathy[278,279]. Reverse shoulder arthroplasty is particularly useful when the subscapularis and the posterosuperior cuff are irreparable, as well as in the presence of associated arthritis. However, a subset of patients — individuals with an irreparable cuff tear, no arthritis and good preoperative active motion — are particularly at risk of dissatisfaction after reverse arthroplasty[280].

Outlook

Several important unmet needs remain in the field of rotator cuff degeneration and repair (Box 3). Much of the focus of ongoing research revolves around using orthobiologics such as PRP, growth factors, MSCs and bone marrow aspirate concentrate, to improve tendon–bone healing and tendinopathy. Preliminary findings from experimental models and clinical studies are encouraging but are in the early stages of research[281,282].

A population of MSCs reside in the subacromial bursa, which are responsive to inflammatory stimuli, indicating an as-yet-unexplored biological role in the context of rotator cuff disease[283]. Bursa–tendon crosstalk has an interesting clinical relevance and could be a novel target in the management of shoulder disorders. Indeed, using a rat model of rotator cuff injury and repair, proteomic profiling of the bursa demonstrated increased cytokine expression and MSC proliferation after rotator cuff tears, probably to protect the adjacent intact tissue and to maintain the morphology of the underlying bone[65]. The bursa, therefore, may have an initiating and essential role in healing by acting as a potential cellular source to promote healing after repair[81].

Collagen injections have been used to treat rotator cuff tendinopathy and to support arthroscopic repair. Their mechanism of action is not completely understood, but they have been hypothesized to induce regenerative pathways, to stimulate tenocyte proliferation and migration, and to increase endogenous collagen synthesis to restore collagen fibres in damaged tendons[284–287]. Integrin receptors in fibroblasts are activated and, consequently, the growth factor cascade initiates the synthesis of endogenous collagen, healing the damaged collagen fibres and leading to proper alignment[288–292]. Despite the use of different types of collagens and injection protocols, or applying different PROs, studies have shown clinically and functionally relevant improvements.

Novel surgical procedures to improve outcomes of rotator cuff repair are consistently being attempted, but management of large and massive tears remains a considerable challenge. In patients with massive rotator cuff tears (>5 cm), repair of the superior capsule as well as the rotator cuff has been reported to improve retear rates at early follow up[293,294]. The superior capsule defect has been defined as the essential lesion of rotator cuff tears[295], and several researchers recommend its repair to restore shoulder biomechanics, preventing the rise of the humeral head in the postoperative period[296,297]. It is also thought to provide an additional source of autologous tenocytes, which may improve the biology of the repair.

The long head of the biceps tendon, that is rich in tenocytes and fibroblasts, is a major stabilizer of the humeral head preventing superior migration and reinforcing repair[298–300]. Its use for cuff repair may provide a local autologous source of collagen, and can be incorporated in the repair arthroscopically with no further surgical exposure or donor site morbidity[298].

Optimal management of shoulder disability may be influenced by the more detailed understanding of the natural history of disease and the anticipated operative outcomes. Machine learning employs computer algorithms and statistical analysis to determine complex trends and patterns, which can be difficult to perform in a clinical setting. Studies have shown promising results in accurately predicting postoperative scores. This methodology may be improved to support preoperative counselling, planning and resource allocation[301].

Overall, rotator cuff pathology is a substantial clinical problem with room for improvements in our understanding of pathophysiology, and future research should focus on methods to optimize outcomes of treatment.

Published online: 08 February 2024

Box 3

Unmet needs in the treatment of rotator cuff pathology

Basic science

- Determine the pathophysiology of rotator cuff pain
- Understand the molecular pathways responsible for tendon degeneration
- Develop strategies to improve the biological basis of tendon–bone healing
- Understand the relationship and pathophysiology of muscle degeneration
- Develop pharmacological strategies to enhance muscle quality after rotator cuff repair

Diagnosis and management

- Evaluate genetics of rotator cuff disease — is it preventable at all?
- Predictive modelling of who will benefit from surgery versus non-operative management
- Predictive modelling of tear onset and progression
- Determine pathophysiology of tendon degeneration in specific disease states (for example, diabetes mellitus)

Perioperative and postoperative

- Predictive modelling of surgical outcomes
- Develop strategies to choose optimal repair configuration or biological augmentation
- Optimize salvage options (tendon transfer, reverse, etc.) for irreparable tears
- Improve muscle quality after repair with physical therapy modalities
- Accelerate recovery after surgery
- Improve sleep after surgery

References

1. Gray, M., Wallace, A. & Aldridge, S. Assessment of shoulder pain for non-specialists. *BMJ* **355**, i5783 (2016).
2. Rugg, C. M., Gallo, R. A., Craig, E. V. & Feeley, B. T. The pathogenesis and management of cuff tear arthropathy. *J. Shoulder Elbow Surg.* **27**, 2271–2283 (2018).
3. Millar, N. L. et al. Tendinopathy. *Nat. Rev. Dis. Primers* **7**, 1 (2021).
4. Keener, J. D. et al. Patterns of tear progression for asymptomatic degenerative rotator cuff tears. *J. Shoulder Elbow Surg.* **24**, 1845–1851 (2015).
5. Keener, J. D. et al. A prospective evaluation of survivorship of asymptomatic degenerative rotator cuff tears. *J. Bone Joint Surg. Am.* **97**, 89–98 (2015).
6. Nie, D., Zhou, Y., Wang, W., Zhang, J. & Wang, J. H. Mechanical overloading induced-activation of mTOR signaling in tendon stem/progenitor cells contributes to tendinopathy development. *Front. Cell Dev. Biol.* **9**, 687856 (2021).
7. Gladstone, J. N., Bishop, J. Y., Lo, I. K. & Flatow, E. L. Fatty infiltration and atrophy of the rotator cuff do not improve after rotator cuff repair and correlate with poor functional outcome. *Am. J. Sports Med.* **35**, 719–728 (2007).
8. Davies, M. R. et al. Rotator cuff tear size regulates fibroadipogenic progenitor number and gene expression profile in the supraspinatus independent of patient age. *Am. J. Sports Med.* **50**, 208–215 (2022).
9. Feeley, B. T. et al. Human rotator cuff tears have an endogenous, inducible stem cell source capable of improving muscle quality and function after rotator cuff repair. *Am. J. Sports Med.* **48**, 2660–2668 (2020).
10. Yanik, E. L., Chamberlain, A. M. & Keener, J. D. Trends in rotator cuff repair rates and comorbidity burden among commercially insured patients younger than the age of 65 years, United States 2007-2016. *JSES Rev. Rep. Tech.* **1**, 309–316 (2021).
11. Keener, J. D., Steger-May, K., Stobbs, G. & Yamaguchi, K. Asymptomatic rotator cuff tears: patient demographics and baseline shoulder function. *J. Shoulder Elbow Surg.* **19**, 1191–1198 (2010).
12. Hinsley, H., Ganderton, C., Arden, N. K. & Carr, A. J. Prevalence of rotator cuff tendon tears and symptoms in a Chingford general population cohort, and the resultant impact on UK health services: a cross-sectional observational study. *BMJ Open* **12**, e059175 (2022).
13. Yamamoto, A. et al. Prevalence and risk factors of a rotator cuff tear in the general population. *J. Shoulder Elbow Surg.* **19**, 116–120 (2010).
14. Minagawa, H. et al. Prevalence of symptomatic and asymptomatic rotator cuff tears in the general population: from mass-screening in one village. *J. Orthop.* **10**, 8–12 (2013).
15. Keener, J. D., Patterson, B. M., Orvets, N. & Chamberlain, A. M. Degenerative rotator cuff tears: refining surgical indications based on natural history data. *J. Am. Acad. Orthop. Surg.* **27**, 156–165 (2019).
16. Kim, H. M. et al. Relationship of tear size and location to fatty degeneration of the rotator cuff. *J. Bone Joint Surg. Am.* **92**, 829 (2010).
17. Yamaguchi, K. et al. The demographic and morphological features of rotator cuff disease. A comparison of asymptomatic and symptomatic shoulders. *J. Bone Joint Surg. Am.* **88**, 1699–1704 (2006).
18. Mall, N. A. et al. Symptomatic progression of asymptomatic rotator cuff tears: a prospective study of clinical and sonographic variables. *J. Bone Joint Surg. Am.* **92**, 2623–2633 (2010).
19. Yamaguchi, K. et al. Natural history of asymptomatic rotator cuff tears: a longitudinal analysis of asymptomatic tears detected sonographically. *J. Shoulder Elbow Surg.* **10**, 199–203 (2001).
20. Teunis, T., Lubberts, B., Reilly, B. T. & Ring, D. A systematic review and pooled analysis of the prevalence of rotator cuff disease with increasing age. *J. Shoulder Elbow Surg.* **23**, 1913–1921 (2014).
21. Harvie, P. et al. Genetic influences in the aetiology of tears of the rotator cuff. Sibling risk of a full-thickness tear. *J. Bone Joint Surg. Br.* **86**, 696–700 (2004).
22. Gwilym, S. E. et al. Genetic influences in the progression of tears of the rotator cuff. *J. Bone Joint Surg. Br.* **91**, 915–917 (2009).
23. Zhao, J. et al. Risk factors for supraspinatus tears: a meta-analysis of observational studies. *Orthop. J. Sports Med.* **9**, 23259671211042826 (2021).
24. Tashjian, R. Z., Granger, E. K., Farnham, J. M., Cannon-Albright, L. A. & Teerlink, C. C. Genome-wide association study for rotator cuff tears identifies two significant single-nucleotide polymorphisms. *J. Shoulder Elbow Surg.* **25**, 174–179 (2016).
25. Tashjian, R. Z., Kim, S. K., Roche, M. D., Jones, K. B. & Teerlink, C. C. Genetic variants associated with rotator cuff tearing utilizing multiple population-based genetic resources. *J. Shoulder Elbow Surg.* **30**, 520–531 (2021).
26. Yanik, E. L. et al. Identification of a novel genetic marker for risk of degenerative rotator cuff disease surgery in the UK biobank. *J. Bone Joint Surg. Am.* **103**, 1259–1267 (2021).
27. Kim, S. K., Nguyen, C., Jones, K. B. & Tashjian, R. Z. A genome-wide association study for shoulder impingement and rotator cuff disease. *J. Shoulder Elbow Surg.* **30**, 2134–2145 (2021).
28. Yoshida, K. et al. Association of superoxide-induced oxidative stress with rotator cuff tears in human patients. *J. Orthop. Res.* **38**, 212–218 (2020).
29. Zhao, J. et al. What factors are associated with symptomatic rotator cuff tears: a meta-analysis. *Clin. Orthop. Relat. Res.* **480**, 96–105 (2022).
30. Huang, S. W. et al. Autoimmune connective tissue diseases and the risk of rotator cuff repair surgery: a population-based retrospective cohort study. *BMJ Open* **9**, e023848 (2019).
31. Huang, S. W. et al. Diabetes mellitus increases the risk of rotator cuff tear repair surgery: a population-based cohort study. *J. Diabetes Complications* **30**, 1473–1477 (2016).
32. Huang, S. W., Wu, C. W., Lin, L. F., Liou, T. H. & Lin, H. W. Gout can increase the risk of receiving rotator cuff tear repair surgery. *Am. J. Sports Med.* **45**, 2355–2363 (2017).
33. Mandalia, K. et al. Social determinants of health influence clinical outcomes of patients undergoing rotator cuff repair: a systematic review. *J. Shoulder Elbow Surg.* **32**, 419–434 (2023).
34. Chung, S. W. et al. Altered gene and protein expressions in torn rotator cuff tendon tissues in diabetic patients. *Arthroscopy* **33**, 518–526 e1 (2017).
35. Yeom, J. W. et al. Postoperative HbA1c level as a predictor of rotator cuff integrity after arthroscopic rotator cuff repair in patients with type 2 diabetes. *Orthop. J. Sports Med.* **11**, 23259671221145987 (2023).
36. Kim, M. S., Rhee, S. M. & Cho, N. S. Increased HbA1c levels in diabetics during the postoperative 3-6 months after rotator cuff repair correlated with increased retear rates. *Arthroscopy* **39**, 176–182 (2023).
37. Wilde, B. et al. Abnormal laboratory values for metabolic and hormonal syndromes are prevalent among patients undergoing rotator cuff repair. *Arthrosc. Sports Med. Rehabil.* **5**, e695–e701 (2023).
38. Smith, K. M. et al. The effect of sex hormone deficiency on the incidence of rotator cuff repair: analysis of a large insurance database. *J. Bone Joint Surg. Am.* **104**, 774–779 (2022).
39. Soslowsky, L. J. et al. Neer Award 1999. Overuse activity injures the supraspinatus tendon in an animal model: a histologic and biomechanical study. *J. Shoulder Elbow Surg.* **9**, 79–84 (2000).
40. Carpenter, J. E., Flanagan, C. L., Thomopoulos, S., Yian, E. H. & Soslowsky, L. J. The effects of overuse combined with intrinsic or extrinsic alterations in an animal model of rotator cuff tendinosis. *Am. J. Sports Med.* **26**, 801–807 (1998).
41. Keener, J. D. et al. Shoulder activity level and progression of degenerative cuff disease. *J. Shoulder Elbow Surg.* **26**, 1500–1507 (2017).
42. Teerlink, C. C., Cannon-Albright, L. A. & Tashjian, R. Z. Significant association of full-thickness rotator cuff tears and estrogen-related receptor-β (ESRRB). *J. Shoulder Elbow Surg.* **24**, e31–e35 (2015).
43. Torchia, M. T. et al. Evaluation of survivorship of asymptomatic degenerative rotator cuff tears in patients 65 years and younger: a prospective analysis with long-term follow-up. *J. Shoulder Elbow Surg.* **32**, 1432–1444 (2023).
44. Miranda, H., Viikari-Juntura, E., Heistaro, S., Heliovaara, M. & Riihimaki, H. A population study on differences in the determinants of a specific shoulder disorder versus nonspecific shoulder pain without clinical findings. *Am. J. Epidemiol.* **161**, 847–855 (2005).
45. Svendsen, S. W. et al. Work above shoulder level and degenerative alterations of the rotator cuff tendons: a magnetic resonance imaging study. *Arthritis Rheum.* **50**, 3314–3322 (2004).
46. Dalboge, A., Frost, P., Andersen, J. H. & Svendsen, S. W. Cumulative occupational shoulder exposures and surgery for subacromial impingement syndrome: a nationwide Danish cohort study. *Occup. Environ. Med.* **71**, 750–756 (2014).
47. Dalboge, A., Frost, P., Andersen, J. H. & Svendsen, S. W. Surgery for subacromial impingement syndrome in relation to occupational exposures, lifestyle factors and diabetes mellitus: a nationwide nested case-control study. *Occup. Environ Med.* **74**, 728–736 (2017).
48. Meyers, A. R. et al. Work-related risk factors for rotator cuff syndrome in a prospective study of manufacturing and healthcare workers. *Hum. Factors* **65**, 419–434 (2023).
49. Yanik, E. L. et al. Occupational demands associated with rotator cuff disease surgery in the UK Biobank. *Scand. J. Work. Environ Health* **49**, 53–63 (2023).
50. Maman, E. et al. Outcome of nonoperative treatment of symptomatic rotator cuff tears monitored by magnetic resonance imaging. *J. Bone Joint Surg. Am.* **91**, 1898–1906 (2009).
51. Chalmers, P. N. et al. Does the critical shoulder angle correlate with rotator cuff tear progression? *Clin. Orthop. Relat. Res.* **475**, 1608–1617 (2017).
52. Rojas Lievano, J., Bautista, M., Woodcock, S., Fierro, G. & Gonzalez, J. C. Controversy on the association of the critical shoulder angle and the development of degenerative rotator cuff tears: is there a true association? A meta-analytical approach. *Am. J. Sports Med.* **50**, 2552–2560 (2022).
53. Jeong, J. Y. et al. Location of rotator cuff tear initiation: a magnetic resonance imaging study of 191 shoulders. *Am. J. Sports Med.* **46**, 649–655 (2018).
54. Lohr, J. F. & Uhthoff, H. K. The microvascular pattern of the supraspinatus tendon. *Clin. Orthop. Relat. Res.* **254**, 35–38 (1990).
55. Burkhart, S. S., Esch, J. C. & Jolson, R. S. The rotator crescent and rotator cable: an anatomic description of the shoulder's "suspension bridge". *Arthroscopy* **9**, 611–616 (1993).
56. Mesiha, M. M., Derwin, K. A., Sibole, S. C., Erdemir, A. & McCarron, J. A. The biomechanical relevance of anterior rotator cuff cable tears in a cadaveric shoulder model. *J. Bone Joint Surg. Am.* **95**, 1817–1824 (2013).
57. Kim, H. M. et al. Location and initiation of degenerative rotator cuff tears: an analysis of three hundred and sixty shoulders. *J. Bone Joint Surg. Am.* **92**, 1088–1096 (2010).
58. Namdari, S. et al. Characteristics of small to medium-sized rotator cuff tears with and without disruption of the anterior supraspinatus tendon. *J. Shoulder Elbow Surg.* **23**, 20–27 (2014).
59. Moosmayer, S., Tariq, R., Stiris, M. & Smith, H. J. The natural history of asymptomatic rotator cuff tears: a three-year follow-up of fifty cases. *J. Bone Joint Surg. Am.* **95**, 1249–1255 (2013).

60. Safran, O., Schroeder, J., Bloom, R., Weil, Y. & Milgrom, C. Natural history of nonoperatively treated symptomatic rotator cuff tears in patients 60 years old or younger. *Am. J. Sports Med.* **39**, 710–714 (2011).
61. Hebert-Davies, J. et al. Progression of fatty muscle degeneration in atraumatic rotator cuff tears. *J. Bone Joint Surg. Am.* **99**, 832–839 (2017).
62. Neer, C. S.2nd Anterior acromioplasty for the chronic impingement syndrome in the shoulder: a preliminary report. *J. Bone Joint Surg. Am.* **54**, 41–50 (1972).
63. Overbeek, C. L. et al. Altered cocontraction patterns of humeral head depressors in patients with subacromial pain syndrome: a cross-sectional electromyography analysis. *Clin. Orthop. Relat. Res.* **477**, 1862–1868 (2019).
64. Overbeek, C. L. et al. Increased co-contraction of arm adductors is associated with a favorable course in subacromial pain syndrome. *J. Shoulder Elbow Surg.* **27**, 1925–1931 (2018).
65. Levy, B. J. et al. Subacromial bursal tissue and surrounding matrix of patients undergoing rotator cuff repair contains progenitor cells. *Arthroscopy* **38**, 1115–1123 (2022).
66. Kriscenski, D. E. et al. Characterization of murine subacromial bursal-derived cells. *Connect. Tissue Res.* **63**, 287–297 (2022).
67. Morikawa, D. et al. Analysis of patient factors affecting in vitro characteristics of subacromial bursal connective tissue progenitor cells during rotator cuff repair. *J. Clin. Med.* **10**, 4006 (2021).
68. Marshall, B. P. et al. The subacromial bursa is a key regulator of the rotator cuff and a new therapeutic target for improving repair. Preprint at *bioRxiv* https://doi.org/10.1101/2023.07.01.547347 (2023).
69. McFarland, E. G. et al. Impingement is not impingement: the case for calling it "rotator cuff disease". *Muscles Ligaments Tendons J.* **3**, 196–200 (2013).
70. Maffulli, N., Khan, K. M. & Puddu, G. Overuse tendon conditions: time to change a confusing terminology. *Arthroscopy* **14**, 840–843 (1998).
71. Sharma, P. & Maffulli, N. Tendon injury and tendinopathy: healing and repair. *J. Bone Joint Surg. Am.* **87**, 187–202 (2005).
72. D'Addona, A., Maffulli, N., Formisano, S. & Rosa, D. Inflammation in tendinopathy. *Surgeon* **15**, 297–302 (2017).
73. Dakin, S. G. et al. Inflammation activation and resolution in human tendon disease. *Sci. Transl. Med.* **7**, 311ra173 (2015).
74. Akbar, M. et al. Single cell and spatial transcriptomics in human tendon disease indicate dysregulated immune homeostasis. *Ann. Rheum. Dis.* **80**, 1494–1497 (2021).
75. Millar, N. L. et al. IL-17A mediates inflammatory and tissue remodelling events in early human tendinopathy. *Sci. Rep.* **6**, 27149 (2016).
76. Franklin, S. L. et al. Up-regulation of glutamate in painful human supraspinatus tendon tears. *Am. J. Sports Med.* **42**, 1955–1962 (2014).
77. Dean, B. J., Snelling, S. J., Dakin, S. G., Javaid, M. K. & Carr, A. J. In vitro effects of glutamate and N-methyl-D-aspartate receptor (NMDAR) antagonism on human tendon derived cells. *J. Orthop. Res.* **33**, 1515–1522 (2015).
78. Abate, M. et al. Oxidative stress and abnormal tendon sonographic features in elite soccer players (a pilot study). *Rev. Bras. Ortop.* **56**, 432–437 (2021).
79. Zapp, C. et al. Mechanoradicals in tensed tendon collagen as a source of oxidative stress. *Nat. Commun.* **11**, 2315 (2020).
80. Liang, Y. et al. Quercetin reduces tendon adhesion in rat through suppression of oxidative stress. *BMC Musculoskelet. Disord.* **21**, 608 (2020).
81. Yuan, T. et al. Proteomic analysis reveals rotator cuff injury caused by oxidative stress. *Ther. Adv. Chronic Dis.* **12**, 2040622320987057 (2021).
82. Lui, P. P. Y., Zhang, X., Yao, S., Sun, H. & Huang, C. Roles of oxidative stress in acute tendon injury and degenerative tendinopathy – a target for intervention. *Int. J. Mol. Sci.* **23**, 3571 (2022).
83. Wunderli, S. L. et al. Tendon response to matrix unloading is determined by the patho-physiological niche. *Matrix Biol.* **89**, 11–26 (2020).
84. Joshi, S. K. et al. mTOR regulates fatty infiltration through SREBP-1 and PPARγ after a combined massive rotator cuff tear and suprascapular nerve injury in rats. *J. Orthop. Res.* **31**, 724–730 (2013).
85. Lui, P. P. Y. Tendinopathy in diabetes mellitus patients – epidemiology, pathogenesis, and management. *Scand. J. Med. Sci. Sports* **27**, 776–787 (2017).
86. Pouzaud, F. et al. In vitro discrimination of fluoroquinolones toxicity on tendon cells: involvement of oxidative stress. *J. Pharmacol. Exp. Ther.* **308**, 394–402 (2004).
87. Lehner, C. et al. Bupivacaine induces short-term alterations and impairment in rat tendons. *Am. J. Sports Med.* **41**, 1411–1418 (2013).
88. Sajithlal, G. B., Chithra, P. & Chandrakasan, G. Effect of curcumin on the advanced glycation and cross-linking of collagen in diabetic rats. *Biochem. Pharmacol.* **56**, 1607–1614 (1998).
89. Lansdown, D. A. et al. Preoperative IDEAL (Iterative Decomposition of Echoes of Asymmetrical Length) magnetic resonance imaging rotator cuff muscle fat fractions are associated with rotator cuff repair outcomes. *J. Shoulder Elbow Surg.* **28**, 1936–1941 (2019).
90. Meyer, G. A., Thomopoulos, S., Abu-Amer, Y. & Shen, K. C. Tenotomy-induced muscle atrophy is sex-specific and independent of NFκB. *Elife* **11**, e82016 (2022).
91. Liu, X. et al. Evaluation of Akt/mTOR activity in muscle atrophy after rotator cuff tears in a rat model. *J. Orthop. Res.* **30**, 1440–1446 (2012).
92. Davies, M. R. et al. Rat rotator cuff muscle responds differently from hindlimb muscle to a combined tendon-nerve injury. *J. Orthop. Res.* **33**, 1046–1053 (2015).
93. Zheng, R. et al. Leucine attenuates muscle atrophy and autophagosome formation by activating PI3K/AKT/mTOR signaling pathway in rotator cuff tears. *Cell Tissue Res.* **378**, 113–125 (2019).
94. Valencia, A. P., Iyer, S. R., Spangenburg, E. E., Gilotra, M. N. & Lovering, R. M. Impaired contractile function of the supraspinatus in the acute period following a rotator cuff tear. *BMC Musculoskelet. Disord.* **18**, 436 (2017).
95. Jackman, R. W., Cornwell, E. W., Wu, C. L. & Kandarian, S. C. Nuclear factor-κB signalling and transcriptional regulation in skeletal muscle atrophy. *Exp. Physiol.* **98**, 19–24 (2013).
96. Davies, M. R. et al. Muscle stem cell activation in a mouse model of rotator cuff injury. *J. Orthop. Res.* **36**, 1370–1376 (2018).
97. Brack, A. S. & Munoz-Canoves, P. The ins and outs of muscle stem cell aging. *Skelet. Muscle* **6**, 1 (2016).
98. Barruet, E. et al. Functionally heterogeneous human satellite cells identified by single cell RNA sequencing. *Elife* **9**, e51576 (2020).
99. Hwang, A. B. & Brack, A. S. Muscle stem cells and aging. *Curr. Top. Dev. Biol.* **126**, 299–322 (2018).
100. Brack, A. S. et al. Increased Wnt signaling during aging alters muscle stem cell fate and increases fibrosis. *Science* **317**, 807–810 (2007).
101. Brack, A. S. & Rando, T. A. Intrinsic changes and extrinsic influences of myogenic stem cell function during aging. *Stem Cell Rev.* **3**, 226–237 (2007).
102. Gerber, C., Meyer, D. C., Schneeberger, A. G., Hoppeler, H. & von Rechenberg, B. Effect of tendon release and delayed repair on the structure of the muscles of the rotator cuff: an experimental study in sheep. *J. Bone Joint Surg. Am.* **86**, 1973–1982 (2004).
103. Chung, S. W. et al. Effect of hypercholesterolemia on fatty infiltration and quality of tendon-to-bone healing in a rabbit model of a chronic rotator cuff tear: electrophysiological, biomechanical, and histological analyses. *Am. J. Sports Med.* **44**, 1153–1164 (2016).
104. Joe, A. W. et al. Muscle injury activates resident fibro/adipogenic progenitors that facilitate myogenesis. *Nat. Cell Biol.* **12**, 153–163 (2010).
105. Uezumi, A. et al. Fibrosis and adipogenesis originate from a common mesenchymal progenitor in skeletal muscle. *J. Cell Sci.* **124**, 3654–3664 (2011).
106. Uezumi, A., Fukada, S., Yamamoto, N., Takeda, S. & Tsuchida, K. Mesenchymal progenitors distinct from satellite cells contribute to ectopic fat cell formation in skeletal muscle. *Nat. Cell Biol.* **12**, 143–152 (2010).
107. Wosczyna, M. N. et al. Targeting microRNA-mediated gene repression limits adipogenic conversion of skeletal muscle mesenchymal stromal cells. *Cell Stem Cell* **28**, 1323–1334. e8 (2021).
108. Wang, X. et al. Diverse effector and regulatory functions of fibro/adipogenic progenitors during skeletal muscle fibrosis in muscular dystrophy. *iScience* **26**, 105775 (2023).
109. Consalvi, S. et al. Determinants of epigenetic resistance to HDAC inhibitors in dystrophic fibro-adipogenic progenitors. *EMBO Rep.* **23**, e54721 (2022).
110. Theret, M., Rossi, F. M. V. & Contreras, O. Evolving roles of muscle-resident fibro-adipogenic progenitors in health, regeneration, neuromuscular disorders, and aging. *Front. Physiol.* **12**, 673404 (2021).
111. Moratal, C., Arrighi, N., Dechesne, C. A. & Dani, C. Control of muscle fibro-adipogenic progenitors by myogenic lineage is altered in aging and Duchenne muscular dystrophy. *Cell Physiol. Biochem.* **53**, 1029–1045 (2019).
112. Lee, C. et al. Rotator cuff fibro-adipogenic progenitors demonstrate highest concentration, proliferative capacity, and adipogenic potential across muscle groups. *J. Orthop. Res.* **38**, 1113–1121 (2020).
113. Davies, M. R. et al. TGF-β small molecule inhibitor SB431542 reduces rotator cuff muscle fibrosis and fatty infiltration by promoting fibro/adipogenic progenitor apoptosis. *PLoS ONE* **11**, e0155486 (2016).
114. Shirasawa, H. et al. Retinoic acid receptor agonists suppress muscle fatty infiltration in mice. *Am. J. Sports Med.* **49**, 332–339 (2021).
115. Itoigawa, Y., Kishimoto, K. N., Sano, H., Kaneko, K. & Itoi, E. Molecular mechanism of fatty degeneration in rotator cuff muscle with tendon rupture. *J. Orthop. Res.* **29**, 861–866 (2011).
116. Davis, M. E. et al. Simvastatin reduces fibrosis and protects against muscle weakness after massive rotator cuff tear. *J. Shoulder Elbow Surg.* **24**, 280–287 (2015).
117. Contreras, O., Rossi, F. M. V. & Theret, M. Origins, potency, and heterogeneity of skeletal muscle fibro-adipogenic progenitors – time for new definitions. *Skelet. Muscle* **11**, 16 (2021).
118. Biferali, B., Proietti, D., Mozzetta, C. & Madaro, L. Fibro-adipogenic progenitors cross-talk in skeletal muscle: the social network. *Front. Physiol.* **10**, 1074 (2019).
119. Malecova, B. et al. Dynamics of cellular states of fibro-adipogenic progenitors during myogenesis and muscular dystrophy. *Nat. Commun.* **9**, 3670 (2018).
120. Garcia, S. M. et al. Distinct human stem cell subpopulations drive adipogenesis and fibrosis in musculoskeletal injury. Preprint at *bioRxiv* https://doi.org/10.1101/2023.07.28.551038 (2023).
121. Davies, M. R. et al. Muscle-derived beige adipose precursors secrete promyogenic exosomes that treat rotator cuff muscle degeneration in mice and are identified in humans by single-cell RNA sequencing. *Am. J. Sports Med.* **50**, 2247–2257 (2022).
122. Wang, Z. et al. β_3-Adrenergic receptor agonist treats rotator cuff fatty infiltration by activating beige fat in mice. *J. Shoulder Elbow Surg.* **30**, 373–386 (2021).
123. Wang, Z. et al. Intramuscular brown fat activation decreases muscle atrophy and fatty infiltration and improves gait after delayed rotator cuff repair in mice. *Am. J. Sports Med.* **48**, 1590–1600 (2020).
124. Lee, C. et al. Beige FAPs transplantation improves muscle quality and shoulder function after massive rotator cuff tears. *J. Orthop. Res.* **38**, 1159–1166 (2020).

125. Bunker, D. L., Ilie, V., Ilie, V. & Nicklin, S. Tendon to bone healing and its implications for surgery. *Muscles Ligaments Tendons J.* **4**, 343–350 (2014).
126. Tresoldi, I. et al. Tendon's ultrastructure. *Muscles Ligaments Tendons J.* **3**, 2–6 (2013).
127. Moser, H. L. et al. Cell lineage tracing and functional assessment of supraspinatus tendon healing in an acute repair murine model. *J. Orthop. Res.* **39**, 1789–1799 (2021).
128. Rodeo, S. A., Arnoczky, S. P., Torzilli, P. A., Hidaka, C. & Warren, R. F. Tendon-healing in a bone tunnel. A biomechanical and histological study in the dog. *J. Bone Joint Surg. Am.* **75**, 1795–1803 (1993).
129. Rodeo, S. A., Suzuki, K., Deng, X. H., Wozney, J. & Warren, R. F. Use of recombinant human bone morphogenetic protein-2 to enhance tendon healing in a bone tunnel. *Am. J. Sports Med.* **27**, 476–488 (1999).
130. Hashimoto, Y., Yoshida, G., Toyoda, H. & Takaoka, K. Generation of tendon-to-bone interface "enthesis" with use of recombinant BMP-2 in a rabbit model. *J. Orthop. Res.* **25**, 1415–1424 (2007).
131. Bedi, A. et al. The effect of matrix metalloproteinase inhibition on tendon-to-bone healing in a rotator cuff repair model. *J. Shoulder Elbow Surg.* **19**, 384–391 (2010).
132. Kovacevic, D. & Rodeo, S. A. Biological augmentation of rotator cuff tendon repair. *Clin. Orthop. Relat. Res.* **466**, 622–633 (2008).
133. Lim, J. K. et al. Enhancement of tendon graft osteointegration using mesenchymal stem cells in a rabbit model of anterior cruciate ligament reconstruction. *Arthroscopy* **20**, 899–910 (2004).
134. Pill, S. G., Phillips, J., Kissenberth, M. J. & Hawkins, R. J. Decision making in massive rotator cuff tears. *Instr. Course Lect.* **61**, 97–111 (2012).
135. Carter, A. N. & Erickson, S. M. Proximal biceps tendon rupture: primarily an injury of middle age. *Phys. Sportsmed.* **27**, 95–101 (1999).
136. Millar, N. L. et al. Frozen shoulder. *Nat. Rev. Dis. Primers* **8**, 59 (2022).
137. Hegedus, E. J. et al. Which physical examination tests provide clinicians with the most value when examining the shoulder? Update of a systematic review with meta-analysis of individual tests. *Br. J. Sports Med.* **46**, 964–978 (2012).
138. Hermans, J. et al. Does this patient with shoulder pain have rotator cuff disease? The rational clinical examination systematic review. *JAMA* **310**, 837–847 (2013).
139. Alqunaee, M., Galvin, R. & Fahey, T. Diagnostic accuracy of clinical tests for subacromial impingement syndrome: a systematic review and meta-analysis. *Arch. Phys. Med. Rehabil.* **93**, 229–236 (2012).
140. Micheroli, R. et al. Correlation of findings in clinical and high resolution ultrasonography examinations of the painful shoulder. *J. Ultrason.* **15**, 29–44 (2015).
141. Silva, L. et al. Accuracy of physical examination in subacromial impingement syndrome. *Rheumatology* **47**, 679–683 (2008).
142. Jain, N. B. et al. The diagnostic accuracy of special tests for rotator cuff tear: the ROW cohort study. *Am. J. Phys. Med. Rehabil.* **96**, 176–183 (2017).
143. Schiefer, M. et al. Clinical diagnosis of subscapularis tendon tear using the bear hug semiological maneuver. *Rev. Bras. Ortop.* **47**, 588–592 (2012).
144. Ernstbrunner, L. et al. Chronic pseudoparalysis needs to be distinguished from pseudoparesis: a structural and biomechanical analysis. *Am. J. Sports Med.* **49**, 291–297 (2021).
145. Hamada, K., Yamanaka, K., Uchiyama, Y., Mikasa, T. & Mikasa, M. A radiographic classification of massive rotator cuff tear arthritis. *Clin. Orthop. Relat. Res.* **469**, 2452 (2011).
146. van der Reijden, J. J. et al. The value of radiographic markers in the diagnostic work-up of rotator cuff tears, an arthroscopic correlated study. *Skelet. Radiol.* **49**, 55–64 (2020).
147. Pearsall, A. W. et al. Radiographic findings associated with symptomatic rotator cuff tears. *J. Shoulder Elbow Surg.* **12**, 122–127 (2003).
148. Samilson, R. L. & Prieto, V. Dislocation arthropathy of the shoulder. *J. Bone. Joint Surg. Am.* **65**, 456–460 (1983).
149. Brox, J., Lereim, P., Merckoll, E. & Finnanger, A. M. Radiographic classification of glenohumeral arthrosis. *Acta Orthop. Scand.* **74**, 186–189 (2003).
150. Goutallier, D. et al. Acromio humeral distance less than six millimeter: its meaning in full-thickness rotator cuff tear. *Orthop. Traumatol. Surg. Res.* **97**, 246–251 (2011).
151. Bahrs, C., Lingenfelter, E., Fischer, F., Walters, E. M. & Schnabel, M. Mechanism of injury and morphology of the greater tuberosity fracture. *J. Shoulder Elbow Surg.* **15**, 140–147 (2006).
152. Speed, C. A. & Hazleman, B. L. Calcific tendinitis of the shoulder. *N. Engl. J. Med.* **340**, 1582–1584 (1999).
153. Elsharkawi, M., Cakir, B., Reichel, H. & Kappe, T. Reliability of radiologic glenohumeral osteoarthritis classifications. *J. Shoulder Elbow Surg.* **22**, 1063–1067 (2013).
154. Smith, T. O., Daniell, H., Geere, J.-A., Toms, A. P. & Hing, C. B. The diagnostic accuracy of MRI for the detection of partial- and full-thickness rotator cuff tears in adults. *Magn. Reson. Imaging* **30**, 336–346 (2012).
155. Roy, J.-S. et al. Diagnostic accuracy of ultrasonography, MRI and MR arthrography in the characterisation of rotator cuff disorders: a systematic review and meta-analysis. *Br. J. Sports Med.* **49**, 1316–1328 (2015).
156. Cofield, R. H. et al. Surgical repair of chronic rotator cuff tears. A prospective long-term study. *J. Bone Joint Surg. Am.* **83**, 71–77 (2001).
157. Meyer, D. C., Wieser, K., Farshad, M. & Gerber, C. Retraction of supraspinatus muscle and tendon as predictors of success of rotator cuff repair. *Am. J. Sports Med.* **40**, 2242–2247 (2012).
158. Jungmann, P. M. et al. Reliable semiquantitative whole-joint MRI score for the shoulder joint: the Shoulder Osteoarthritis Severity (SOAS) score. *J. Magn. Reson. Imaging* **49**, e152–e163 (2019).
159. Fuchs, B., Weishaupt, D., Zanetti, M., Hodler, J. & Gerber, C. Fatty degeneration of the muscles of the rotator cuff: assessment by computed tomography versus magnetic resonance imaging. *J. Shoulder Elbow Surg.* **8**, 599–605 (1999).
160. Burkhart, S. S., Barth, J. R., Richards, D. P., Zlatkin, M. B. & Larsen, M. Arthroscopic repair of massive rotator cuff tears with stage 3 and 4 fatty degeneration. *Arthroscopy* **23**, 347–354 (2007).
161. Goutallier, D., Postel, J.-M., Bernageau, J., Lavau, L. & Voisin, M.-C. Fatty muscle degeneration in cuff ruptures: pre- and postoperative evaluation by CT scan. *Clin. Orthop. Relat. Res.* **304**, 78–83 (1994).
162. Goutallier, D., Postel, J.-M., Gleyze, P., Leguilloux, P. & Van Driessche, S. Influence of cuff muscle fatty degeneration on anatomic and functional outcomes after simple suture of full-thickness tears. *J. Shoulder Elbow Surg.* **12**, 550–554 (2003).
163. Lippe, J. et al. Inter-rater agreement of the Goutallier, Patte, and Warner classification scores using preoperative magnetic resonance imaging in patients with rotator cuff tears. *Arthroscopy* **28**, 154–159 (2012).
164. Schiefer, M. et al. Intraobserver and interobserver agreement of Goutallier classification applied to magnetic resonance images. *J. Shoulder Elbow Surg.* **24**, 1314–1321 (2015).
165. Slabaugh, M. A. et al. Interobserver and intraobserver reliability of the Goutallier classification using magnetic resonance imaging: proposal of a simplified classification system to increase reliability. *Am. J. Sports Med.* **40**, 1728–1734 (2012).
166. Agten, C. A., Rosskopf, A. B., Gerber, C. & Pfirrmann, C. W. Quantification of early fatty infiltration of the rotator cuff muscles: comparison of multi-echo Dixon with single-voxel MR spectroscopy. *Eur. Radiol.* **26**, 3719–3727 (2016).
167. Lansdown, D. A. et al. A prospective, quantitative evaluation of fatty infiltration before and after rotator cuff repair. *Orthop. J. Sports Med.* **5**, 2325967117718537 (2017).
168. Lee, S. et al. Magnetic resonance rotator cuff fat fraction and its relationship with tendon tear severity and subject characteristics. *J. Shoulder Elbow Surg.* **24**, 1442–1451 (2015).
169. Nardo, L. et al. Quantitative assessment of fat infiltration in the rotator cuff muscles using water–fat MRI. *J. Magn. Reson. Imaging* **39**, 1178–1185 (2014).
170. Kwon, J., Kim, S. H., Lee, Y. H., Kim, T. I. & Oh, J. H. The rotator cuff healing index: a new scoring system to predict rotator cuff healing after surgical repair. *Am. J. Sports Med.* **47**, 173–180 (2019).
171. Lenza, M. et al. Magnetic resonance imaging, magnetic resonance arthrography and ultrasonography for assessing rotator cuff tears in people with shoulder pain for whom surgery is being considered. *Cochrane Database Syst. Rev.* **2013**, CD009020 (2013).
172. Lecouvet, F. E. et al. Multidetector spiral CT arthrography of the shoulder: clinical applications and limits, with MR arthrography and arthroscopic correlations. *Eur. J. Radiol.* **68**, 120–136 (2008).
173. Nazarian, L. N. et al. Imaging algorithms for evaluating suspected rotator cuff disease: Society of Radiologists in Ultrasound consensus conference statement. *Radiology* **267**, 589–595 (2013).
174. Middleton, W. D. et al. Sonography and MRI of the shoulder: comparison of patient satisfaction. *AJR Am. J. Roentgenol.* **183**, 1449–1452 (2004).
175. Parker, L. et al. Musculoskeletal imaging: Medicare use, costs, and potential for cost substitution. *J. Am. Coll. Radiol.* **5**, 182–188 (2008).
176. Iannotti, J. P. et al. Accuracy of office-based ultrasonography of the shoulder for the diagnosis of rotator cuff tears. *J. Bone Joint Surg. Am.* **87**, 1305–1311 (2005).
177. Farooqi, A. S. et al. Diagnostic accuracy of ultrasonography for rotator cuff tears: a systematic review and meta-analysis. *Orthop. J. Sports Med.* **9**, 23259671211035106 (2021).
178. Khoury, V., Cardinal, É. & Brassard, P. Atrophy and fatty infiltration of the supraspinatus muscle: sonography versus MRI. *AJR Am. J. Roentgenol.* **190**, 1105–1111 (2008).
179. Aranha, L., Eapen, C., Patel, V. D., Prabhakar, A. J. & Hariharan, K. Muscle fatigue response of rotator cuff muscles in different postures. *Arch. Orthop. Trauma. Surg.* **143**, 3191–3199 (2023).
180. Griffith, K. M. et al. Review of human supraspinatus tendon mechanics. Part I: fatigue damage accumulation and failure. *J. Shoulder Elbow Surg.* **31**, 2671–2677 (2022).
181. Ranger, T. A., Wong, A. M., Cook, J. L. & Gaida, J. E. Is there an association between tendinopathy and diabetes mellitus? A systematic review with meta-analysis. *Br. J. Sports Med.* **50**, 982–989 (2016).
182. Lewis, J. S. & Sandford, F. M. Rotator cuff tendinopathy: is there a role for polyunsaturated fatty acids and antioxidants? *J. Hand Ther.* **22**, 49–55 (2009).
183. Angeline, M. E. et al. Effect of diet-induced vitamin D deficiency on rotator cuff healing in a rat model. *Am. J. Sports Med.* **42**, 27–34 (2014).
184. Kuo, L. T. et al. Depression increases the risk of rotator cuff tear and rotator cuff repair surgery: a nationwide population-based study. *PLoS ONE* **14**, e0225778 (2019).
185. Song, A. et al. Comparative time to improvement in nonoperative and operative treatment of rotator cuff tears. *J. Bone Joint Surg. Am.* **102**, 1142–1150 (2020).
186. Kuhn, J. E. et al. Effectiveness of physical therapy in treating atraumatic full-thickness rotator cuff tears: a multicenter prospective cohort study. *J. Shoulder Elbow Surg.* **22**, 1371–1379 (2013).
187. Dunn, W. R. et al. 2013 Neer Award: predictors of failure of nonoperative treatment of chronic, symptomatic, full-thickness rotator cuff tears. *J. Shoulder Elbow Surg.* **25**, 1303–1311 (2016).
188. Moosmayer, S. et al. Tendon repair compared with physiotherapy in the treatment of rotator cuff tears: a randomized controlled study in 103 cases with a five-year follow-up. *J. Bone Joint Surg. Am.* **96**, 1504–1514 (2014).

189. Kukkonen, J. et al. Treatment of nontraumatic rotator cuff tears: a randomized controlled trial with two years of clinical and imaging follow-up. *J. Bone Joint Surg. Am.* **97**, 1729–1737 (2015).
190. Moosmayer, S. et al. At a 10-year follow-up, tendon repair is superior to physiotherapy in the treatment of small and medium-sized rotator cuff tears. *J. Bone Joint Surg. Am.* **101**, 1050–1060 (2019).
191. Levy, O., Mullett, H., Roberts, S. & Copeland, S. The role of anterior deltoid reeducation in patients with massive irreparable degenerative rotator cuff tears. *J. Shoulder Elbow Surg.* **17**, 863–870 (2008).
192. Bennell, K. et al. Efficacy of standardised manual therapy and home exercise programme for chronic rotator cuff disease: randomised placebo controlled trial. *BMJ* **340**, c2756 (2010).
193. Bernhardsson, S., Klintberg, I. H. & Wendt, G. K. Evaluation of an exercise concept focusing on eccentric strength training of the rotator cuff for patients with subacromial impingement syndrome. *Clin. Rehabil.* **25**, 69–78 (2011).
194. Ludewig, P. M. & Reynolds, J. F. The association of scapular kinematics and glenohumeral joint pathologies. *J. Orthop. Sports Phys. Ther.* **39**, 90–104 (2009).
195. Cools, A. M. et al. Rehabilitation of scapular muscle balance: which exercises to prescribe? *Am. J. Sports Med.* **35**, 1744–1751 (2007).
196. Boudreault, J. et al. The efficacy of oral non-steroidal anti-inflammatory drugs for rotator cuff tendinopathy: a systematic review and meta-analysis. *J. Rehabil. Med.* **46**, 294–306 (2014).
197. Mazières, B., Rouanet, S., Guillon, Y., Scarsi, C. & Reiner, V. Topical ketoprofen patch in the treatment of tendinitis: a randomized, double blind, placebo controlled study. *J. Rheumatol.* **32**, 1563–1570 (2005).
198. Tangtiphaiboontana, J. et al. The effects of nonsteroidal anti-inflammatory medications after rotator cuff surgery: a randomized, double-blind, placebo-controlled trial. *J. Shoulder Elbow Surg.* **30**, 1990–1997 (2021).
199. Desai, V. S. et al. Increasing numbers of shoulder corticosteroid injections within a year preoperatively may be associated with a higher rate of subsequent revision rotator cuff surgery. *Arthroscopy* **35**, 45–50 (2019).
200. Werner, B. C. et al. The timing of elective shoulder surgery after shoulder injection affects postoperative infection risk in Medicare patients. *J. Shoulder Elbow Surg.* **25**, 390–397 (2016).
201. Bhattacharjee, S., Lee, W., Lee, M. J. & Shi, L. L. Preoperative corticosteroid joint injections within 2 weeks of shoulder arthroscopies increase postoperative infection risk. *J. Shoulder Elbow Surg.* **28**, 2098–2102 (2019).
202. Xiang, X. N. et al. Conservative treatment of partial-thickness rotator cuff tears and tendinopathy with platelet-rich plasma: a systematic review and meta-analysis. *Clin. Rehabil.* **35**, 1661–1673 (2021).
203. Pang, L. et al. Platelet-rich plasma injection can be a viable alternative to corticosteroid injection for conservative treatment of rotator cuff disease: a meta-analysis of randomized controlled trials. *Arthroscopy* **39**, 402–421.e1 (2023).
204. Jo, C. H. et al. Intratendinous injection of autologous adipose tissue-derived mesenchymal stem cells for the treatment of rotator cuff disease: a first-in-human trial. *Stem Cell* **36**, 1441–1450 (2018).
205. Paloneva, J. et al. Declining incidence of acromioplasty in Finland. *Acta Orthop.* **86**, 220–224 (2015).
206. Oh, J. H., Kim, J. Y., Lee, H. K. & Choi, J. A. Classification and clinical significance of acromial spur in rotator cuff tear: heel-type spur and rotator cuff tear. *Clin. Orthop. Relat. Res.* **468**, 1542–1550 (2010).
207. Farfaras, S., Sernert, N., Rostgard Christensen, L., Hallstrom, E. K. & Kartus, J. T. Subacromial decompression yields a better clinical outcome than therapy alone: a prospective randomized study of patients with a minimum 10-year follow-up. *Am. J. Sports Med.* **46**, 1397–1407 (2018).
208. Farfaras, S., Sernert, N., Hallstrom, E. & Kartus, J. Comparison of open acromioplasty, arthroscopic acromioplasty and physiotherapy in patients with subacromial impingement syndrome: a prospective randomised study. *Knee Surg. Sports Traumatol. Arthrosc.* **24**, 2181–2191 (2016).
209. Waterman, B. R. et al. Randomized trial of arthroscopic rotator cuff with or without acromioplasty: no difference in patient-reported outcomes at long-term follow-up. *Arthroscopy* **37**, 3072–3078 (2021).
210. Paavola, M. et al. Subacromial decompression versus diagnostic arthroscopy for shoulder impingement: a 5-year follow-up of a randomised, placebo surgery controlled clinical trial. *Br. J. Sports Med.* **55**, 99–107 (2021).
211. Kolk, A. et al. Does acromioplasty result in favorable clinical and radiologic outcomes in the management of chronic subacromial pain syndrome? A double-blinded randomized clinical trial with 9 to 14 years' follow-up. *J. Shoulder Elbow Surg.* **26**, 1407–1415 (2017).
212. Ketola, S., Lehtinen, J. T. & Arnala, I. Arthroscopic decompression not recommended in the treatment of rotator cuff tendinopathy: a final review of a randomised controlled trial at a minimum follow-up of ten years. *Bone Joint J.* **99-B**, 799–805 (2017).
213. Woodmass, J. M. et al. Arthroscopic rotator cuff repair with and without acromioplasty in the treatment of full-thickness rotator cuff tears: long-term outcomes of a multicenter, randomized controlled trial. *J. Bone Joint Surg. Am.* **104**, 2101–2107 (2022).
214. Jensen, A. R. et al. Evaluation of the trends, concomitant procedures, and complications with open and arthroscopic rotator cuff repairs in the Medicare population. *Orthop. J. Sports Med.* **5**, 2325967117731310 (2017).
215. Buyukdogan, K. et al. Long-term outcomes after arthroscopic transosseous-equivalent repair: clinical and magnetic resonance imaging results of rotator cuff tears at a minimum follow-up of 10 years. *J. Shoulder Elbow Surg.* **30**, 2767–2777 (2021).
216. Randelli, P. S. et al. Long-term results of arthroscopic rotator cuff repair: initial tear size matters: a prospective study on clinical and radiological results at a minimum follow-up of 10 years. *Am. J. Sports Med.* **47**, 2659–2669 (2019).
217. Jeong, H. J., Nam, K. P., Yeo, J. H., Rhee, S. M. & Oh, J. H. Retear after arthroscopic rotator cuff repair results in functional outcome deterioration over time. *Arthroscopy* **38**, 2399–2412 (2022).
218. Le, B. T., Wu, X. L., Lam, P. H. & Murrell, G. A. Factors predicting rotator cuff retears: an analysis of 1000 consecutive rotator cuff repairs. *Am. J. Sports Med.* **42**, 1134–1142 (2014).
219. Guo, A. A., Stitz, D. J., Lam, P. & Murrell, G. A. C. Tear size and stiffness are important predictors of retear: an assessment of factors associated with repair integrity at 6 months in 1,526 rotator cuff repairs. *JB JS Open Access* **7**, e22.00006 (2022).
220. Maher, A. et al. Do age, demographics, and tear characteristics affect outcomes after rotator cuff repair? results of over 2000 rotator cuff repairs at 5-year follow-up. *Orthop. J. Sports Med.* **10**, 23259671221119222 (2022).
221. Gerber, C. et al. Neer Award 2007: reversion of structural muscle changes caused by chronic rotator cuff tears using continuous musculotendinous traction. An experimental study in sheep. *J. Shoulder Elbow Surg.* **18**, 163–171 (2009).
222. Zhao, J. et al. Risk factors affecting rotator cuff retear after arthroscopic repair: a meta-analysis and systematic review. *J. Shoulder Elbow Surg.* **30**, 2660–2670 (2021).
223. Gatto, A. P., Hu, D. A., Feeley, B. T. & Lansdown, D. Dyslipidemia is associated with risk for rotator cuff repair failure: a systematic review and meta-analysis. *JSES Rev. Rep. Tech.* **2**, 302–309 (2022).
224. Yang, Z. et al. Association of obesity with high retears and complication rates, and low functional scores after rotator cuff repair: a systematic review and meta-analysis. *J. Shoulder Elbow Surg.* **32**, 2400–2411 (2023).
225. Fan, N. et al. The effects of smoking on clinical and structural outcomes after rotator cuff repair: a systematic review and meta-analysis. *J. Shoulder Elbow Surg.* **31**, 656–667 (2022).
226. Sheean, A. J., Hartzler, R. U. & Burkhart, S. S. Arthroscopic rotator cuff repair in 2019: linked, double row repair for achieving higher healing rates and optimal clinical outcomes. *Arthroscopy* **35**, 2749–2755 (2019).
227. Bedeir, Y. H., Schumaier, A. P., Abu-Sheasha, G. & Grawe, B. M. Type 2 retear after arthroscopic single-row, double-row and suture bridge rotator cuff repair: a systematic review. *Eur. J. Orthop. Surg. Traumatol.* **29**, 373–382 (2019).
228. Malavolta, E. A. et al. Prognostic factors for clinical outcomes after arthroscopic rotator cuff repair. *Orthop. J. Sports Med.* **11**, 2325967123160738 (2023).
229. Bishop, M. E. et al. Biomechanical and clinical comparison of suture techniques in arthroscopic rotator cuff repair. *JBJS Rev.* **5**, e3 (2017).
230. Hohmann, E. et al. Single- versus double-row repair for full-thickness rotator cuff tears using suture anchors. A systematic review and meta-analysis of basic biomechanical studies. *Eur. J. Orthop. Surg. Traumatol.* **28**, 859–868 (2018).
231. Millett, P. J., Warth, R. J., Dornan, G. J., Lee, J. T. & Spiegl, U. J. Clinical and structural outcomes after arthroscopic single-row versus double-row rotator cuff repair: a systematic review and meta-analysis of level I randomized clinical trials. *J. Shoulder Elbow Surg.* **23**, 586–597 (2014).
232. Sobhy, M. H., Khater, A. H., Hassan, M. R. & El Shazly, O. Do functional outcomes and cuff integrity correlate after single- versus double-row rotator cuff repair? A systematic review and meta-analysis study. *Eur. J. Orthop. Surg. Traumatol.* **28**, 593–605 (2018).
233. Hernigou, P. et al. Biologic augmentation of rotator cuff repair with mesenchymal stem cells during arthroscopy improves healing and prevents further tears: a case-controlled study. *Int. Orthop.* **38**, 1811–1818 (2014).
234. Cole, B. J. et al. Prospective randomized trial of biologic augmentation with bone marrow aspirate concentrate in patients undergoing arthroscopic rotator cuff repair. *Am. J. Sports Med.* **51**, 1234–1242 (2023).
235. Feltri, P. et al. Platelet-rich plasma does not improve clinical results in patients with rotator cuff disorders but reduces the retear rate. A systematic review and meta-analysis. *Knee Surg. Sports Traumatol. Arthrosc.* **31**, 1940–1952 (2023).
236. Lavoie-Gagne, O. et al. Double-row repair with platelet-rich plasma optimizes retear rates after small to medium full-thickness rotator cuff repair: a systematic review and network meta-analysis of randomized controlled trials. *Arthroscopy* **38**, 2714–2729 (2022).
237. Zhang, C., Cai, Y. Z. & Wang, Y. Injection of leukocyte-poor platelet-rich plasma for moderate-to-large rotator cuff tears does not improve clinical outcomes but reduces retear rates and fatty infiltration: a prospective, single-blinded randomized study. *Arthroscopy* **38**, 2381–2388.e1 (2022).
238. Liu, B., Jeong, H. J., Yeo, J. H. & Oh, J. H. Efficacy of intraoperative platelet-rich plasma augmentation and postoperative platelet-rich plasma booster injection for rotator cuff healing: a randomized controlled clinical trial. *Orthop. J. Sports Med.* **9**, 23259671211006100 (2021).
239. Hurley, E. T., Lim Fat, D., Moran, C. J. & Mullett, H. The efficacy of platelet-rich plasma and platelet-rich fibrin in arthroscopic rotator cuff repair: a meta-analysis of randomized controlled trials. *Am. J. Sports Med.* **47**, 753–761 (2019).
240. Castricini, R. et al. Platelet-rich plasma augmentation for arthroscopic rotator cuff repair: a randomized controlled trial. *Am. J. Sports Med.* **39**, 258–265 (2011).
241. Randelli, P. S., Stoppani, C. A., Santarsiero, G., Nocerino, E. & Menon, A. Platelet-rich plasma in arthroscopic rotator cuff repair: clinical and radiological results of a

prospective randomized controlled trial study at 10-year follow-up. *Arthroscopy* **38**, 51–61 (2022).
242. Oudelaar, B. W., Peerbooms, J. C., Huis In, 'T., Veld, R. & Vochteloo, A. J. H. Concentrations of blood components in commercial platelet-rich plasma separation systems: a review of the literature. *Am. J. Sports Med.* **47**, 479–487 (2019).
243. Oh, J. H., Park, M. S. & Rhee, S. M. Treatment strategy for irreparable rotator cuff tears. *Clin. Orthop. Surg.* **10**, 119–134 (2018).
244. de Marinis, R. et al. Lower trapezius transfer improves clinical outcomes with a rate of complications and reoperations comparable to other surgical alternatives in patients with functionally irreparable rotator cuff tears: a systematic review. *Arthroscopy* https://doi.org/10.1016/j.arthro.2023.06.029 (2023).
245. Mirzayan, R. et al. Emerging treatment options for massive rotator cuff tears: biologic tuberoplasty, balloon arthroplasty, anterior cable reconstruction, lower trapezius transfer. *Instr. Course Lect.* **72**, 223–238 (2023).
246. Saccomanno, M. F. et al. Combined arthroscopic-assisted lower trapezius tendon transfer and superior capsule reconstruction for massive irreparable posterior-superior rotator cuff tears: surgical technique. *Arthrosc. Tech.* **12**, e823–e830 (2023).
247. Galvin, J. W. et al. Outcomes and complications of primary reverse shoulder arthroplasty with minimum of 2 years' follow-up: a systematic review and meta-analysis. *J. Shoulder Elbow Surg.* **31**, e534–e544 (2022).
248. Burden, E. G., Batten, T. J., Smith, C. D. & Evans, J. P. Reverse total shoulder arthroplasty. *Bone Joint J.* **103-B**, 813–821 (2021).
249. Bacle, G., Nove-Josserand, L., Garaud, P. & Walch, G. Long-term outcomes of reverse total shoulder arthroplasty: a follow-up of a previous study. *J. Bone Joint Surg. Am.* **99**, 454–461 (2017).
250. Bulhoff, M. et al. Medium- to long-term outcomes after reverse total shoulder arthroplasty with a standard long stem. *J. Clin. Med* **11**, 2274 (2022).
251. Favard, L. et al. Reverse prostheses in arthropathies with cuff tear: are survivorship and function maintained over time? *Clin. Orthop. Relat. Res.* **469**, 2469–2475 (2011).
252. Zumstein, M., Pinedo, M., Old, J. & Pascal, B. Problems, complications, reoperations, and revisions in reverse total shoulder arthroplasty: a systematic review. *J. Shoulder Elbow Surg.* **20**, 146–157 (2011).
253. Su, F. et al. Incidence, risk factors, and complications of acromial stress fractures after reverse total shoulder arthroplasty. *J. Shoulder Elbow Surg.* **33**, 65–72 (2023).
254. Jeong, H. J. et al. Subacromial notching after reverse total shoulder arthroplasty. *J. Shoulder Elbow Surg.* **32**, 1876–1885 (2023).
255. Cheung, E. V. et al. Instability after reverse total shoulder arthroplasty. *J. Shoulder Elbow Surg.* **27**, 1946–1952 (2018).
256. Schell, L. E. et al. Aseptic glenoid baseplate loosening after reverse total shoulder arthroplasty with a single prosthesis. *J. Shoulder Elbow Surg.* **32**, 1584–1593 (2023).
257. Baksh, N. et al. Does preoperative corticosteroid injection increase the risk of periprosthetic joint infection after reverse shoulder arthroplasty? *J. Shoulder Elbow Surg.* **32**, 1459–1464 (2023).
258. Reddy, R. P., Solomon, D. A., Hughes, J. D., Lesniak, B. P. & Lin, A. Clinical outcomes of rotator cuff repair in patients with concomitant glenohumeral osteoarthritis. *J. Shoulder Elbow Surg.* **31**, S25–S33 (2022).
259. Manop, P., Apivatgaroon, A., Puntu, W. & Chernchujit, B. Risk factors for rotator cuff repair failure and reliability of the rotator cuff healing index (RoHI) in Thai patients: comparison of the RoHI with a modified scoring system. *Orthop. J. Sports Med.* **11**, 23259671231179449 (2023).
260. Jeon, Y. D. et al. Significance of the acromiohumeral distance on stress radiography for predicting healing and function after arthroscopic repair of massive rotator cuff tears. *J. Shoulder Elbow Surg.* **30**, e471–e481 (2021).
261. Davey, M. S. et al. Arthroscopic rotator cuff repair results in improved clinical outcomes and low revision rates at 10-year follow-up: a systematic review. *Arthroscopy* **39**, 452–458 (2023).
262. Sanchez-Sotelo, J. & Athwal, G. S. How to optimize reverse shoulder arthroplasty for irreparable cuff tears. *Curr. Rev. Musculoskelet. Med.* **13**, 553–560 (2020).
263. Tempelhof, S., Rupp, S. & Seil, R. Age-related prevalence of rotator cuff tears in asymptomatic shoulders. *J. Shoulder Elbow Surg.* **8**, 296–299 (1999).
264. Longo, U. G. et al. Anxiety and depressive symptoms correlated to patient-reported outcome measures after rotator cuff repair: a prospective study in the perioperative period. *J. Clin. Med.* **12**, 2999 (2023).
265. Panattoni, N. et al. The influence of psychosocial factors on patient-reported outcome measures in rotator cuff tears pre- and post-surgery: a systematic review. *Qual. Life Res.* **31**, 91–116 (2022).
266. Longo, U. G. et al. Arthroscopic rotator cuff repair improves sleep disturbance and quality of life: a prospective study. *Int. J. Environ. Res. Public Health* **18**, 3797 (2021).
267. Kunze, K. N. et al. Systematic review of sleep quality before and after arthroscopic rotator cuff repair: are improvements experienced and maintained? *Orthop. J. Sports Med.* **8**, 2325967120969224 (2020).
268. Serbest, S., Tiftikçi, U., Askın, A., Yaman, F. & Alpua, M. Preoperative and post-operative sleep quality evaluation in rotator cuff tear patients. *Knee Surg. Sports Traumatol. Arthrosc.* **25**, 2109–2113 (2017).
269. Zheng, E. T., Lowenstein, N. A., Collins, J. E. & Matzkin, E. G. Resolution of sleep disturbance and improved functional outcomes after rotator cuff repair. *Am. J. Sports Med.* **51**, 1852–1858 (2023).
270. Boorman, R. S. et al. What happens to patients when we do not repair their cuff tears? Five-year rotator cuff quality-of-life index outcomes following nonoperative treatment of patients with full-thickness rotator cuff tears. *J. Shoulder Elbow Surg.* **27**, 444–448 (2018).
271. Fucentese, S. F., von Roll, A. L., Pfirrmann, C. W., Gerber, C. & Jost, B. Evolution of nonoperatively treated symptomatic isolated full-thickness supraspinatus tears. *J. Bone Joint Surg. Am.* **94**, 801–808 (2012).
272. Jain, N. B. et al. Comparative effectiveness of operative versus nonoperative treatment for rotator cuff tears: a propensity score analysis from the ROW cohort. *Am. J. Sports Med.* **47**, 3065–3072 (2019).
273. van Deurzen, D. et al. Long-term results of arthroscopic and mini-open repair of small- to medium-size full-thickness rotator cuff tears. *Shoulder Elbow* **11**, 68–76 (2019).
274. Yoo, J. H., Cho, N. S. & Rhee, Y. G. Effect of postoperative repair integrity on health-related quality of life after rotator cuff repair: healed versus retear group. *Am. J. Sports Med.* **41**, 2637–2644 (2013).
275. Galatz, L. M., Griggs, S., Cameron, B. D. & Iannotti, J. P. Prospective longitudinal analysis of postoperative shoulder function : a ten-year follow-up study of full-thickness rotator cuff tears. *J. Bone Joint Surg. Am.* **83**, 1052–1056 (2001).
276. Nicholson, A. D. et al. Minimum 15-year follow-up for clinical outcomes of arthroscopic rotator cuff repair. *J. Shoulder Elbow Surg.* **31**, 1696–1703 (2022).
277. Green, A. et al. Long-term functional and structural outcome of rotator cuff repair in patients 60 years old or less. *JSES Int.* **7**, 58–66 (2023).
278. Gerber, C., Canonica, S., Catanzaro, S. & Ernstbrunner, L. Longitudinal observational study of reverse total shoulder arthroplasty for irreparable rotator cuff dysfunction: results after 15 years. *J. Shoulder Elbow Surg.* **27**, 831–838 (2018).
279. Mulieri, P., Dunning, P., Klein, S., Pupello, D. & Frankle, M. Reverse shoulder arthroplasty for the treatment of irreparable rotator cuff tear without glenohumeral arthritis. *J. Bone Joint Surg. Am.* **92**, 2544–2556 (2010).
280. Hartzler, R. U. et al. Reverse shoulder arthroplasty for massive rotator cuff tear: risk factors for poor functional improvement. *J. Shoulder Elbow Surg.* **24**, 1698–1706 (2015).
281. Fealy, S. et al. Patterns of vascular and anatomical response after rotator cuff repair. *Am. J. Sports Med.* **34**, 120–127 (2006).
282. Randelli, P. et al. History of rotator cuff surgery. *Knee Surg. Sports Traumatol. Arthrosc.* **23**, 344–362 (2015).
283. Minkwitz, S. et al. Histological and molecular features of the subacromial bursa of rotator cuff tears compared to non-tendon defects: a pilot study. *BMC Musculoskelet. Disord.* **22**, 877 (2021).
284. Corrado, B. et al. Ultrasound-guided collagen injections in the treatment of supraspinatus tendinopathy: a case series pilot study. *J. Biol. Regul. Homeost. Agents* **34** (3 Suppl. 2), 33–39 (2020).
285. Corrado, B., Bonini, I., Alessio Chirico, V., Rosano, N. & Gisonni, P. Use of injectable collagen in partial-thickness tears of the supraspinatus tendon: a case report. *Oxf. Med. Case Rep.* **2020**, omaa103 (2020).
286. Randelli, F. et al. Effect of a collagen-based compound on morpho-functional properties of cultured human tenocytes. *Cells* **7**, 246 (2018).
287. Martinello, T. et al. Successful recellularization of human tendon scaffolds using adipose-derived mesenchymal stem cells and collagen gel. *J. Tissue Eng. Regen. Med.* **8**, 612–619 (2014).
288. Jo, Y., Kim, W. J. & Lee, H. Healing of partial tear of the supraspinatus tendon after atelocollagen injection confirmed by MRI: a case report. *Medicine* **99**, e23498 (2020).
289. Suh, D. S. et al. Atelocollagen enhances the healing of rotator cuff tendon in rabbit model. *Am. J. Sports Med.* **45**, 2019–2027 (2017).
290. Canty, E. G. & Kadler, K. E. Procollagen trafficking, processing and fibrillogenesis. *J. Cell Sci.* **118**, 1341–1353 (2005).
291. Hynes, R. O. Integrins: bidirectional, allosteric signaling machines. *Cell* **110**, 673–687 (2002).
292. Massoud, E. I. Healing of subcutaneous tendons: influence of the mechanical environment at the suture line on the healing process. *World J. Orthop.* **4**, 229–240 (2013).
293. Aguado, G., Obando, D. V., Herrera, G. A., Ramirez, A. & Llinas, P. J. Retears of the rotator cuff: an ultrasonographic assessment during the first postoperative year. *Orthop. J. Sports Med.* **7**, 2325967119889049 (2019).
294. Hein, J., Reilly, J. M., Chae, J., Maerz, T. & Anderson, K. Retear rates after arthroscopic single-row, double-row, and suture bridge rotator cuff repair at a minimum of 1 year of imaging follow-up: a systematic review. *Arthroscopy* **31**, 2274–2281 (2015).
295. Mihata, T., McGarry, M. H., Pirolo, J. M., Kinoshita, M. & Lee, T. Q. Superior capsule reconstruction to restore superior stability in irreparable rotator cuff tears: a biomechanical cadaveric study. *Am. J. Sports Med.* **40**, 2248–2255 (2012).
296. Ishihara, Y. et al. Role of the superior shoulder capsule in passive stability of the glenohumeral joint. *J. Shoulder Elbow Surg.* **23**, 642–648 (2014).
297. Mihata, T. et al. A biomechanical cadaveric study comparing superior capsule reconstruction using fascia lata allograft with human dermal allograft for irreparable rotator cuff tear. *J. Shoulder Elbow Surg.* **26**, 2158–2166 (2017).
298. Ji, J. H. et al. Transtendon arthroscopic repair of high grade partial-thickness articular surface tears of the rotator cuff with biceps tendon augmentation: technical note and preliminary results. *Arch. Orthop. Trauma. Surg.* **132**, 335–342 (2012).
299. Park, M. C. et al. Anterior cable reconstruction using the proximal biceps tendon for large rotator cuff defects limits superior migration and subacromial contact without

inhibiting range of motion: a biomechanical analysis. *Arthroscopy* **34**, 2590–2600 (2018).
300. Schmalzl, J. et al. Tendon-derived stem cells from the long head of the biceps tendon: inflammation does not affect the regenerative potential. *Bone Joint Res.* **8**, 414–424 (2019).
301. Potty, A. G. et al. Approaching artificial intelligence in orthopaedics: predictive analytics and machine learning to prognosticate arthroscopic rotator cuff surgical outcomes. *J. Clin. Med.* **12**, 2369 (2023).
302. Akhtar, A., Richards, J. & Monga, P. The biomechanics of the rotator cuff in health and disease – a narrative review. *J. Clin. Orthop. Trauma.* **18**, 150–156 (2021).

Acknowledgements
The authors acknowledge S. E. Feeley for her initial artwork for the Primer.

Author contributions
Introduction (B.T.F. and A.B.); Epidemiology (J.K. and P.M.); Mechanisms/pathophysiology (A.B. and B.T.F.), Diagnosis, screening and prevention (R.J.W.III, J.B. and D.A.L.), Management (O.L., J.H.O. and V.J.S.), Quality of Life, (J.S.-S.) Outlook (N.M.); Overview of Primer (B.T.F.).

Competing interests
The authors declare no competing interests.

Additional information
Peer review information *Nature Reviews Disease Primers* thanks A. Carr; N. Jain, who co-reviewed with R. Prakash; and the other, anonymous, reviewer(s) for their contribution to the peer review of this work.

Publisher's note Springer Nature remains neutral with regard to jurisdictional claims in published maps and institutional affiliations.

Springer Nature or its licensor (e.g. a society or other partner) holds exclusive rights to this article under a publishing agreement with the author(s) or other rightsholder(s); author self-archiving of the accepted manuscript version of this article is solely governed by the terms of such publishing agreement and applicable law.

© Springer Nature Limited 2024